

Chapter 9

Fueling the Functions: The Digestive System

In This Chapter

- ▶ Getting down and dirty with digestion basics
- ▶ Examining the mouth
- ▶ Spending time in the stomach
- ▶ Passing through the intestines and other organs for enzyme digestion

It's time to feed your hunger for knowledge about how nutrients fuel the whole package that is the human body. In this chapter, we help you swallow the basics about getting food into the system and digest the details about how nutrients move into the rest of the body. You also get plenty of practice following the nutritional trail from first bite to final elimination.

Digesting the Basics: It's Alimentary!

Before jumping into a discussion on the alimentary tract, we need to review some basic terms.

- ✓ **Ingestion:** Taking in food
- ✓ **Digestion:** Changing the composition of food — splitting large molecules into smaller ones — to make it usable by the cells
- ✓ **Deglutition:** Swallowing, or moving food from the mouth to the stomach
- ✓ **Absorption:** Occurs when digested food moves through the intestinal wall and into the blood
- ✓ **Egestion:** Eliminating waste materials or undigested foods at the lower end of the digestive tract; also known as *defecation*

The alimentary tract develops early on in a growing embryo. The primitive gut, or *archenteron*, develops from the *endoderm* (inner germinal layer) during the third week after conception, a stage during which the embryo is known as a *gastrula*. At the anterior end (head end), the oral cavity, nasal passages, and salivary glands develop from a small depression called a *stomodaeum* in the *ectoderm* (outer germinal layer). The anal and urogenital structures develop at the opposite, or posterior, end from a depression in the ectoderm called the *proctodaeum*. In other words, the digestive tract develops from an endodermal tube with ectoderm at each end.

Whereas the respiratory tract is a two-way street — oxygen flows in and carbon dioxide flows out — the digestive tract is designed to have a one-way flow (although when you're sick or your body detects something bad in the food you've eaten, what goes down sometimes comes

back up). Under normal conditions, food moves through your body in the following order (see Figure 9-1):

Mouth → Pharynx → Esophagus → Stomach → Small intestine → Large intestine

When you swallow food, it's mixed with digestive enzymes in both saliva and stomach acids. Circular muscles on the inside of the tract and long muscles along the outside of the tract keep the material moving right through defecation at the end of the line.

Chew on these sample questions about the alimentary tract:

1.-5. Match the alimentary tract terms with their descriptions.

- | | |
|--|-----------------------|
| 1. ____ Taking in food | a. Digestion |
| 2. ____ Elimination of waste | b. Ingestion |
| 3. ____ Movement of food from mouth to stomach | c. Deglutition |
| 4. ____ Means of transporting food into the blood | d. Absorption |
| 5. ____ Mechanical/chemical changing of food composition | e. Egestion |

6.-16. Use the terms that follow to identify the parts of the digestive system shown in Figure 9-1.

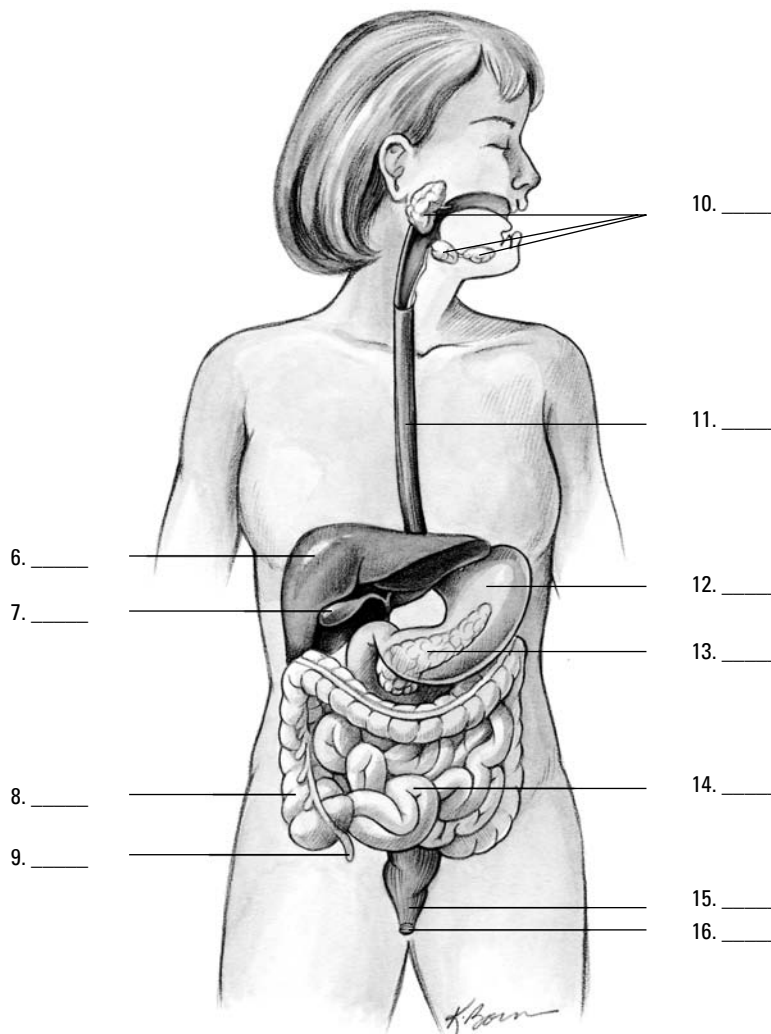


Figure 9-1:
The organs
and glands
of the diges-
tive system.

- a. Pancreas
 - b. Colon
 - c. Liver
 - d. Small intestine
 - e. Salivary glands
 - f. Gallbladder
 - g. Appendix
 - h. Anus
 - i. Esophagus
 - j. Rectum
 - k. Stomach
17. The alimentary tract forms from the following layer(s) of the developing embryo:
- a. Endoderm
 - b. Ectoderm
 - c. Both the endoderm and the ectoderm
 - d. Neither the endoderm nor the ectoderm
18. Identify the correct sequence of the movement of food through the body:
- a. Mouth → Pharynx → Esophagus → Stomach → Small intestine → Large intestine
 - b. Mouth → Esophagus → Pharynx → Stomach → Small intestine → Large intestine
 - c. Mouth → Pharynx → Esophagus → Stomach → Large intestine → Small intestine
 - d. Mouth → Pharynx → Stomach → Esophagus → Small intestine → Large intestine

Nothing to Spit At: Into the Mouth and Past the Teeth

In addition to being very useful for communicating, the mouth serves a number of important roles in the digestive process:

- ✓ Chewing, formally known as *mastication*, breaks down food mechanically into smaller particles.
- ✓ The act of chewing increases blood flow to all the mouth's structures and the lower part of the head.
- ✓ Saliva from *salivary glands* in the mouth helps prepare food to be swallowed and begins the chemical breakdown of carbohydrates.
- ✓ Taste buds on the tongue stimulate saliva production. Interestingly, studies have shown that taste preferences can change in reaction to the body's specific needs. In addition, the smell of food can get gastric juices flowing in preparation for digestion.

The mouth's anatomy begins, of course, with the lips, which are covered by a thin, modified mucous membrane. That membrane is so thin that you can see the red blood

in the underlying capillaries. (That's the unromantic reason for the lips' natural rosy glow.) The mouth itself is divided into two regions defined by the arches of the upper and lower jaws. The *vestibule* is the region between these *dental arches*, cheeks, and lips, whereas the *oral cavity* is the region inside the dental arches.

Entering the vestibule

The inner surface of the lips is covered by a mucous membrane. Sickle-shaped pieces of tissue called *labial frenula* attach the lips to the gums. Within the mucous membrane are *labial glands*, which produce mucus to prevent friction between the lips and the teeth. The cheeks are made up of *buccinator muscles* and a *buccal pad*, a subcutaneous layer of fat. The buccinator muscles keep the food between the teeth during the act of chewing. Elastic tissue in the mucous membrane keeps the lining of the cheeks from forming folds that would be bitten during chewing (usually — most people have bitten the insides of their cheeks at one time or another). Also stashed away in the cheek, just in front of and below each ear, is a *parotid gland*, which is the largest salivary gland; it releases saliva through a duct opposite the second upper molar tooth. Two other pairs of salivary glands also secrete into the mouth: the *submaxillary glands* along the side of the lower jaw and the *sublingual glands* in the floor of the mouth near the chin.

The dental arches are formed by the *maxillae* (upper jaw) and the *mandible* (lower jaw) along with the *gingivae* (gums) and teeth of both jaws. The gingivae are dense, fibrous tissues attached to the teeth and the underlying jaw bones; they're covered by a mucous membrane extending from the lips and cheeks to form a collar around the neck of each tooth. The gums are very vascular (meaning that lots of blood vessels run through them) but poorly innervated (meaning that, fortunately, they're not generally very sensitive to pain).

Teeth rise from openings in the jawbone called *sockets*, or *alveoli*. You have a number of different kinds of teeth, and each has a specific contribution to the process of biting and chewing. Humans get two sets of teeth in a lifetime. The first temporary, or *deciduous*, set is known as *milk teeth*. Babies between 6 months and 2 years old “cut,” or *erupt*, four incisors, two canines, and two molars in each jaw. These teeth are slowly replaced by permanent teeth from about 5 or 6 years of age until the final molars — referred to as *wisdom teeth* — erupt between 17 and 25 years of age.

An adult human has the following 16 teeth in each jaw (for a total set of 32 teeth):

- ✔ Four *incisors*, which are chisel-shaped teeth at the front of the jaw for biting into and cutting food
- ✔ Two *canines*, or *cuspid*s, which are pointed teeth on either side of the incisors for grasping and tearing
- ✔ Four *premolars*, or *bicuspid*s, which are flatter, shallower teeth that come in pairs just behind the canines
- ✔ Six *molars*, which are triplets of broad, flat teeth on either side of the jawbone for grinding and mixing food prior to swallowing

Regardless of type, each tooth has three primary parts, which you can see in Figure 9-2:

- ✔ **Crown:** The part that projects above the gum
- ✔ **Neck:** The region where the gum attaches to the tooth
- ✔ **Root:** The internal structure that firmly fixes the tooth in the alveolus (socket)

Teeth primarily consist of yellowish *dentin* with a layer of *enamel* over the crown and a layer of *cementum* over the root and neck, which are connected to the bone by the *periodontal membrane*. Cementum and dentin are nearly identical in composition to bone; enamel consists of 94 percent calcium phosphate and calcium carbonate and is thickest over the chewing surface of the tooth.

Depending on the structure of the tooth, the root can be a single-, double-, or even triple-pointed structure. In addition, each tooth has a *pulp cavity* at the center that's filled with connective and lymphatic tissue, nerves, and blood vessels that enter the tooth through the root canal via an opening at the bottom called the *apical foramen*. Now you know why it hurts so much when dentists have to drill down and take out that part of an infected tooth!

Moving along the oral cavity

The roof of the oral cavity is formed by both the *hard palate*, a bony structure covered by fibrous tissue and the ever-present mucous membrane, and the *soft palate*, a movable partition of fibromuscular tissue that prevents food and liquid from getting into the nasal cavity. (It's also the tissue that sometimes vibrates in sleep, causing a sonorous grating sound referred to as *snoring*.) The soft palate hangs at the back of the oral cavity in two curved folds that form the palatine arches. The *uvula*, a soft conical process (or piece of tissue), hangs in the center between those folds.

Beyond the soft palate, the *palatopharyngeal* (or *pharyngopalatine*) arch curves sharply toward the midline and blends with the wall of the pharynx, ending at the *dorsum* (back) of the tongue. Another structure, the anterior *palatoglossal* (or *glossopalatine*) arch, starts on the surface of the palate at the base of the uvula and continues in a wide curve forward and downward, ending next to the posterior (back) one-third of the tongue. At the base of these arches and between the folds lie the *palatine tonsils* — if a surgeon hasn't removed them because of frequent childhood infections. The *faucial isthmus* or *oropharynx* is the junction between the oral cavity and the pharynx (described in detail in Chapter 8). It opens during swallowing and closes when you move the dorsum of the tongue against the soft palate when breathing.

The tongue

The tongue, which is a tight bundle of interlaced muscles, and its associated mucous membrane form the floor of the oral cavity. Two distinct groups of muscles — *extrinsic* and *intrinsic* — are used in tandem for mastication (chewing), deglutition (swallowing), and to articulate speech.

- ✔ The extrinsic muscles, which are used to move the tongue in different directions, originate outside the tongue and are attached to the mandible, styloid processes of the temporal bone and the hyoid and, along with a fold of mucous membrane called the *lingual frenulum*, anchor the tongue.
- ✔ The intrinsic muscles are a complex muscle network allowing the tongue to change shape for talking, chewing and swallowing.

Three primary types of *papillae* (nipple-shaped protrusions) cover the tongue's forward upper surface:

- ✔ **Filiform papillae** are fine, brush-like papillae that cover the dorsum, the tip, and the lateral margins of the tongue. They're the most numerous papillae and don't hold any taste buds.

- ✓ **Fungiform papillae** are large, red, mushroom-shaped papillae scattered among the filiform papillae. They have taste buds, which are special receptors that communicate taste signals to the brain.
- ✓ **Vallate papillae**, also called *circumvallate papillae*, are flattened structures, each with a moat-like trough ringing it. There are 12 of these on the tongue, and they surround a V-shaped furrow toward the back of the tongue called the *sulcus terminalis*.

There are no papillae on the back (posterior) one-third of the tongue; that part has only a mucous membrane covering lymphatic tissue, which forms the *lingual tonsils*.

The salivary glands

As we explain in the earlier section “Entering the vestibule,” the oral cavity has three pairs of salivary glands producing saliva. The *submandibular* (or *submaxillary*) salivary glands are about the size of a walnut and release fluid onto the floor of the mouth, under the tongue. The smallest pair of the trio, the *sublingual* salivary glands, lies near the tongue under the oral cavity’s mucous membrane floor to release secretions directly onto the mucous membrane.

And those secretions are nothing to spit at. Saliva does the following:

- ✓ Dissolves and lubricates food to make it easier to swallow
- ✓ Contains *ptyalin*, or *salivary amylase*, an enzyme that initiates chemical digestion of certain carbohydrates
- ✓ Moistens and lubricates the mouth and lips, keeping them pliable and resilient for speech and chewing
- ✓ Frees the mouth and teeth of food, foreign particles, and epithelial cells
- ✓ Produces the sensation of thirst to prevent you from becoming dehydrated

Following are some practice questions regarding the vestibule and oral cavity:



- Q.** The function of the mouth is
- a. Mixing of solid foods with saliva
 - b. Breaking down of the milk protein by the enzyme rennin
 - c. Mastication or the breaking down of food into small particles
 - d. A and c
 - e. A, b, and c

- A.** The correct answer is mixing of solid foods with saliva and mastication. The mouth does lots of things, including mixing saliva into the food to add the enzyme ptyalin, but that’s not rennin. With answer options like these, it’s best to stick to the basics.

19.–30. Use the terms that follow to identify the parts of a tooth shown in Figure 9-2.

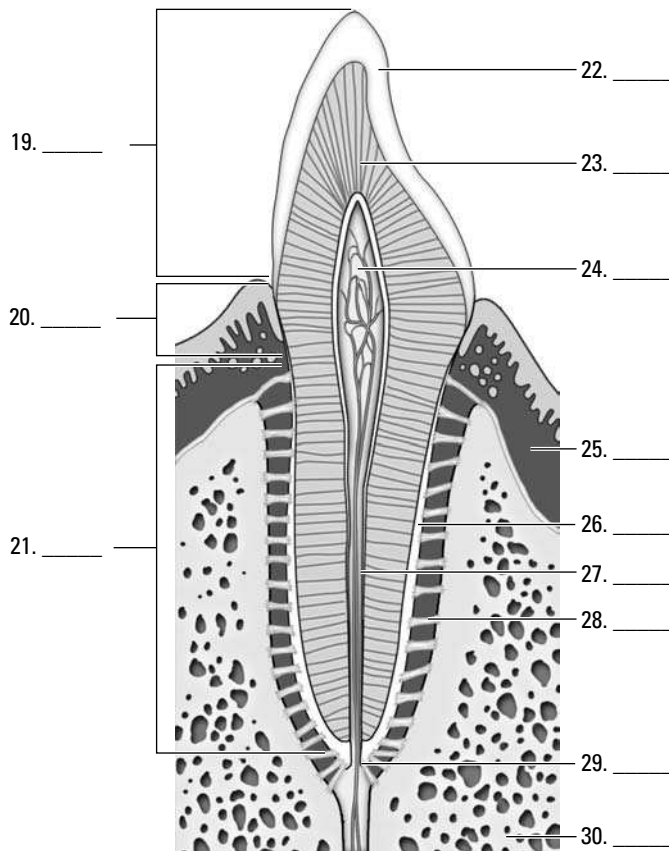


Figure 9-2:
The
composition
of a tooth.

Illustration by Imagineering Media Services Inc.

- a. Root canal
- b. Neck
- c. Bone
- d. Dentin
- e. Crown
- f. Periodontal ligament
- g. Gingiva
- h. Enamel
- i. Root
- j. Apical foramen
- k. Pulp cavity
- l. Cementum

- 31.** The space within the cheek and lip external to the teeth is called the
- a. Rugae
 - b. Villi
 - c. Fundus
 - d. Vestibule
 - e. Pylorus

- 32.** The roof of the oral cavity is formed by
- The hard and soft palates
 - The sulcus terminalis
 - A rigid bony structure covered by fibrous tissue and a mobile partition composed of fibromuscular tissue in a fold of mucous membrane
 - A and c
 - A, b, and c

- 33.** Which of the following statements is *not* true of the teeth?
- The permanent teeth in each human jaw are four incisors, two canines, four premolars, and six molars.
 - Each tooth has a single cuspid anchoring it.
 - The tooth cavity contains the tooth pulp.
 - The enamel consists of 94 percent calcium phosphate and calcium carbonate.
 - Each tooth is composed of a crown, a neck, and a root.

34.-38. Match each description with the proper anatomical structure.

- | | |
|--|---------------------------------|
| 34. _____ Soft conical process projecting from the soft palate | a. Pharyngopalatine arch |
| 35. _____ The junction between the mouth and pharynx | b. Faucial isthmus |
| 36. _____ Forms a collar around the teeth and is poorly innervated | c. Gingivae |
| 37. _____ Sharply curved arch that bends laterally with the walls of the pharynx | d. Glossopalatine arch |
| 38. _____ Arch that starts at the buccal surface of the palate at the base of the uvula and ends alongside the back third of the tongue | e. Uvula |

- 39.** The palatine tonsil is located
- In the posterior wall of the pharynx
 - In the smooth posterior one-third of the tongue
 - In the region between the rigid hard palate and the soft palate
 - Under the mucous membrane of the tongue
 - In the region between the palatopharyngeal and palatoglossal arches

- 40.** The function of saliva is
- To facilitate swallowing
 - To initiate the digestion of certain carbohydrates
 - To moisten and lubricate the mouth and lips
 - A and c
 - A, b, and c

- 41.** The largest salivary gland is the
- Submandibular gland
 - Brunner's gland

- c. Sublingual gland
- d. Submaxillary gland
- e. Parotid gland

42.-44. Match the descriptions with the anatomical structures.

- | | |
|--|-----------------------|
| 42. ____ Fine brush-like structures found covering the dorsum of the tongue | a. Vallate papillae |
| 43. ____ Large mushroom-shaped structures | b. Filiform papillae |
| 44. ____ Large structures, each surrounded by a moat that form a V-shaped furrow in the tongue | c. Fungiform papillae |

Stomaching the Body's Fuel

Deglutition (swallowing) occurs in three phases:

1. **The tip of the tongue elevates slightly, pushing against the hard palate, sliding food onto the back of the tongue, and ultimately propelling it toward the pharynx.**
2. **Tensor muscles tighten the palate while levator muscles raise it until the palate meets the pharyngeal wall, sealing off the nasopharynx from the oropharynx.**

This action momentarily stops breathing and ensures that food and fluid won't regurgitate through the nose — unless someone makes you laugh, of course.

3. **The *bolus* (food mass) heads “down the hatch.”**

The pharynx is an oval fibrous muscular sac, about 5 inches long. It opens into the nasal cavity, the oral cavity, the larynx, and the esophagus. On the lateral walls are located the openings to the Eustachian tubes, which connect with the middle ear. In the posterior wall is a mass of lymphatic tissue, the pharyngeal tonsil or adenoid.

This “hatch,” borrowed nautical slang for the *esophagus*, is approximately 10 inches long and $\frac{1}{2}$ inch in diameter and carries food through three body regions: the neck, the thorax, and the abdomen. It's not a straight tube, but rather curves slightly to the left as it passes through the diaphragm 1 inch to the left of the midline. The very thick walls of the esophagus are lined with non-keratinized stratified squamous epithelium and include a fibrous outer layer made up of elastic fibers that permit *distention* during swallowing (think of a snake swallowing a whole egg — there's some major stretching going on there). A muscular layer contains both longitudinal and circular layers of smooth muscle. The circular layers contract in sequence, like a series of shrinking and expanding rings, in a movement called *peristalsis* that forces the bolus downward. The longitudinal layers act in concert with the circular muscles, pulling the esophagus over the bolus as it moves downward.

All this pushing and pulling ultimately releases the bolus into the stomach, a pear-shaped bag of an organ that lies just beneath the ribs and diaphragm. About 1 foot long and $\frac{1}{2}$ foot wide, a human stomach's normal capacity is about 1 quart. When empty, the stomach's mucous lining lies in folds called *rugae*; rugae allow expansion of the tummy when you gorge and then shrink the stomach when it's empty to decrease the surface area exposed to acid. Food enters the upper end of the stomach, called the *cardiac* region, through a ring of muscles called the *cardiac sphincter*, which generally remains closed to prevent gastric acids from moving up into the esophagus. The

dome-shaped area below the cardiac region is called the *fundus region*; it expands superiorly with really big meals. The lower part of the stomach, shaped like the letter J, is the *pylorus*. The middle part of the *body* of the stomach forms a large curve called the *greater curvature*. The right, much shorter, border of the stomach's body is called the *lesser curvature*. The far end of the stomach remains closed off by the *pyloric sphincter* until its contents have been digested sufficiently to pass into the *duodenum* of the small intestine.

The wall of the stomach consists of three layers of smooth muscle lined by mucous membrane and covered by the peritoneum (see Figure 9-3). The fibers of the outer layer of muscle run longitudinally, the middle layer of muscle consists of circular fibers that encircle the stomach, and the inner layer of muscle fibers runs obliquely only along the fundus region. The stomach's mucous membrane is covered with nonciliated columnar epithelium containing mucous glands.

The three types of gastric glands in the stomach's *epithelium* (lining) are

- ✔ **Cardiac glands:** Found in the cardiac region (of course)
- ✔ **Pyloric glands:** Secrete mucous in the pyloric region
- ✔ **Fundic glands:** Lined with chief cells and parietal cells and are located throughout the stomach's body and fundus

The three types of cells in the *mucosa* (lining) of the stomach are

- ✔ **Mucous cells:** Secrete *mucin* (mucous) to protect the mucosa from the high acidity of the gastric juices
- ✔ **Chief cells:** Secrete *pepsinogen*, a precursor to the enzyme pepsin that helps break down certain proteins into peptides. (Chief cells in children also produce an enzyme called *rennin*, not found in adults, which acts upon milk proteins.)
- ✔ **Parietal cells:** Lie alongside chief cells and secrete the hydrochloric acid that combines with pepsinogen to form pepsin to catalyze protein digestion

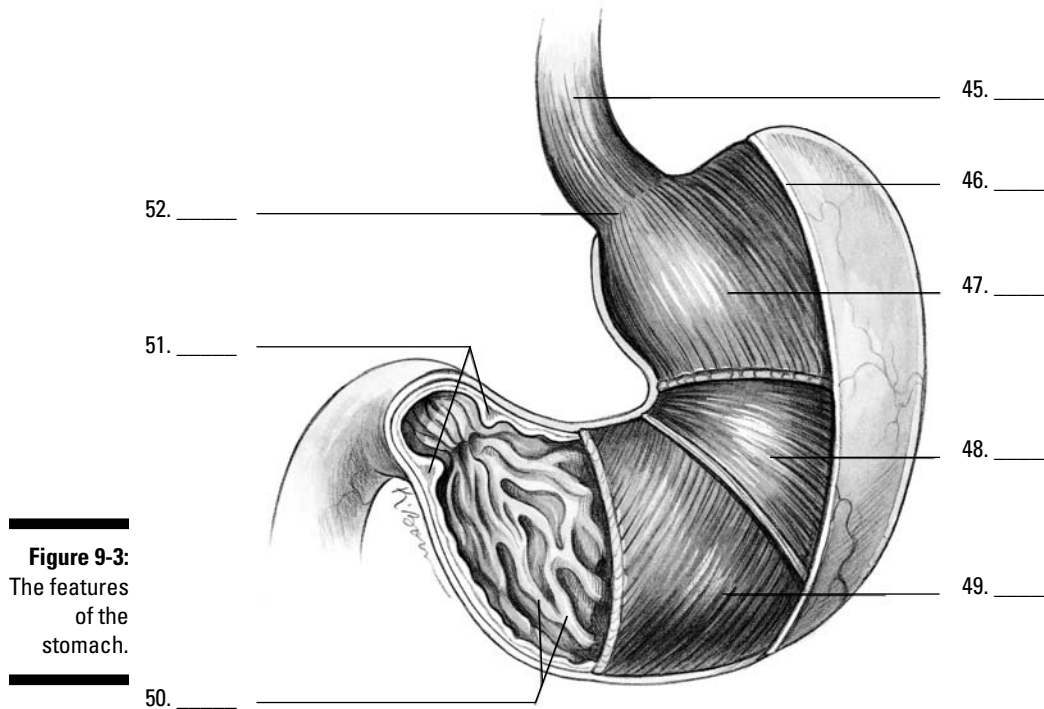
The peristaltic contractions that get the bolus into the stomach aren't limited to the esophagus. Instead, peristalsis continues into the musculature of the stomach and stimulates the release of a hormone called *gastrin*. Within minutes, *gastrin* triggers secretion of gastric juices that reduce the bolus of food to a thick semiliquid mass called *chyme*, which passes through the pyloric sphincter into the small intestine within one to four hours of the food's consumption.



Gastric juices are thin, colorless fluids with an extremely acid pH that ranges from 1 to 4. The quantity of acid released depends on the amount and type of food being digested.

One more part attached to the stomach that we should mention is the *greater omentum*. This is a peritoneal fold that hangs like an apron from the greater curvature of the stomach all the way down to the transverse colon, covering all the small intestine and most of the large intestine. Also called a *caul* or *velum*, this lining can be laden with fat, particularly in obese people.

45.-52. Use the terms that follow to identify the anatomy of the stomach shown in Figure 9-3.



- a. Circular muscle layer
 - b. Esophagus
 - c. Rugae of the mucosa
 - d. Cardiac sphincter
 - e. Serosa
 - f. Oblique muscle layer
 - g. Pyloric sphincter
 - h. Longitudinal muscle layer
- 53.** The sequential contraction of circular muscles as food moves through the esophagus is called
- a. Perispasmic contractions
 - b. Periprostatic contractions
 - c. Fibrillation
 - d. Peristalsis
 - e. Rugae
- 54.** Two muscular rings control movement of food into and out of the stomach. They're called
- a. Enzymes
 - b. Intestines
 - c. Sphincters
 - d. Fundic glands
 - e. Rugae

55. The lower part of the stomach that's shaped like a J is called the
- Esophagus
 - Pylorus
 - Peritoneal fold
 - Cardiac region
 - Fundus region
56. Food that's ready to leave the stomach has been reduced to a thick, semiliquid mass called
- Omentum
 - Gastric juices
 - Peritoneum
 - Chyme
 - Enzymes

Breaking Down the Work of Digestive Enzymes

So what exactly does all the work of digesting and breaking down food? That question brings you back into the realm of proteins. Proteins called *enzymes* act as catalysts, meaning that they initiate and accelerate chemical reactions without themselves being permanently changed in the reaction. Enzymes are very picky proteins indeed; they're effective only in their own pH range, they catalyze only a single chemical reaction, they act on a specific substance called a *substrate*, and they function best at 98.6 degrees Fahrenheit, which just happens to be normal body temperature!

The following sections take you on a tour of the organs in which digestive enzymes do their job.

Small intestine

Most enzyme reactions — in fact most digestion and practically all absorption of nutrients — takes place in the small intestine. Stretching 7 meters (which is nearly 23 feet!), this long snake of an organ extends from the stomach's pylorus to the *ileocecal junction* (the point where the small intestine meets the large intestine), gradually diminishing in diameter along the way.

Three regions of the small intestine play unique roles as chyme moves through it:

- ✓ **Duodenum:** The first section of the small intestine is also the shortest and widest section. As partially digested food enters the duodenum, its acidity stimulates the intestine to secrete the intestinal hormone *enterocrinin*, which controls the secretion of intestinal juices, stimulates the pancreas to secrete its juices, and stimulates the liver to secrete bile. Both the liver and pancreas share a common opening into the duodenum. Lined with large and numerous villi, the duodenum also has *Brunner's glands* that secrete a clear alkaline mucous. The glands are most numerous near the entry to the stomach and decrease in number toward the opposite, or *jejunum*, end.

- ✔ **Jejunum:** This region of the small intestine also contains villi, but unlike the duodenum, it has numerous large circular folds at the beginning that decrease in number toward the *ileum* end.
- ✔ **Ileum:** *Peyer's patches*, which are aggregates of lymph nodes, line this region of the small intestine, becoming largest and most numerous at the *distal* end. The ileum opens into the *cecum* of the large intestine through the *ileocaecal valve*.

A microscopic look at the small intestine reveals circular folds called *plicae circularis*, which project 3 to 10 millimeters into the intestinal lumen and extend anywhere from half to entirely around the tube. These are permanent folds that don't smooth out even when the intestine is distended. Also present are finger-like projections called *villi* that greatly increase the surface area through which the small intestine can absorb nutrients. Each villus contains a network of capillaries and a central lymph vessel, or *lacteal*, which contains a milk-white substance called *chyle*. Simple sugars, amino acids, vitamins, minerals, and water are absorbed by the lacteal and combine to form the triglycerides found in the blood. The surface of the villus is simple columnar epithelium (if you can't recall what that means, flip to Chapter 4). Electron microscopy, which can magnify tissues far more than an optical microscope can, reveals that the surface of each villus is further increased by *microvilli*. Peristalsis continues into the small intestine, shortening and lengthening the villi to mix intestinal juices with food and increase absorption. Intestinal glands lie in the depressions between villi, and packed inside these glands are antimicrobial *Paneth cells* within glands called the *crypts of Lieberkühn*, which secrete enzymes that assist pancreatic enzymes.

Intestinal juices contain three types of enzymes:

- ✔ **Enterokinase** has no enzyme action by itself, but when added to pancreatic juices, it combines with *trypsinogen* to form *trypsin*, which can break down proteins.
- ✔ **Erepsins**, or **proteolytic enzymes**, don't directly digest proteins but instead complete protein digestion started elsewhere. They split polypeptide bonds, separating amino acids.
- ✔ **Inverting enzymes** split disaccharides into monosaccharides as follows:

<i>Enzyme</i>	<i>Disaccharide</i>	<i>Monosaccharides</i>
Maltase	Maltose	Glucose + Glucose
Lactase	Lactose	Glucose + Galactose
Sucrase	Sucrose	Glucose + Fructose

Liver

The largest gland in the body, the liver is divided into a large right lobe and a small left lobe by the *falciform ligament*, another peritoneal fold. Two smaller lobes — the *quadrate* and *caudate* lobes — are found on the lower (inferior) and back (posterior) sides of the right lobe. The quadrate lobe surrounds and cushions the *gallbladder*, a pear-shaped structure that stores and concentrates *bile*, which it empties periodically through the *cystic duct* to the *common bile duct* and on into the duodenum during digestion. Bile aids in the digestion and absorption of fats; it consists of bile pigments, bile salts, and cholesterol.

The liver secretes diluted bile through the *hepatic ducts* into the cystic duct and on into the gallbladder. Liver tissue is made up of rows of cuboidal cells separated by

microscopic blood spaces called *sinusoids*. Blood from the *interlobular veins and arteries* circulates through the sinusoids with food and oxygen for the liver cells, picking up materials along the way. The blood then enters the intralobular veins, which carry it to the sublobular veins, which empty into the hepatic vein, which leads to the inferior vena cava. Bile secreted from the liver cells is carried by *biliary canaliculi* (bile capillaries) to the bile ducts and then to the hepatic ducts.

Considering the number of vital roles the liver plays, the complexity of that process isn't too surprising. Among the liver's various functions are

- ✓ Production of blood plasma proteins including *albumin*, antibodies to fend off disease, a blood anticoagulant called *heparin* that prevents clotting, and bile pigments from red blood cells, the yellow pigment *bilirubin*, and the green bile pigment *biliverdin*
- ✓ Storage of vitamins and minerals as well as glucose in the form of glycogen
- ✓ Conversion and utilization through enzyme activity of fats, carbohydrates, and proteins
- ✓ Filtering and removal of nonfunctioning red blood cells, toxins (isolated by *Kupffer cells* in the liver) and waste products from amino acid breakdown, such as urea and ammonia

Unfortunately, a number of serious diseases can damage the liver. The hepatitis virus inflames the gland, and cirrhosis caused by repeated toxic injury (often through alcohol or other substance abuse) destroys Kupffer cells and replaces them with scar tissue. Also, painful gallstones can develop when cholesterol clumps together to form a center around which the gallstone can form.

Pancreas

Equally important, though not as large as the liver, the *pancreas* looks like a roughly 7-inch long, irregularly shaped prism. It has a broad head lodged in the curve of the duodenum. The head is attached to the body of the gland by a slight constriction called the neck, and the opposite end gradually tapers to form a tail. The pancreatic duct extends from the head to the tail, receiving the ducts of various lobules that make up the gland. It generally joins the common bile duct, but some 40 percent of humans have a pancreatic duct and a common bile duct that open separately into the duodenum.

Uniquely, the pancreas is both an *exocrine gland*, meaning that it releases its secretion externally either directly or through a duct, and an *endocrine gland*, meaning that it produces hormonal secretions that pass directly into the bloodstream without using a duct. However, most of the pancreas is devoted to being an exocrine gland secreting pancreatic juices into the duodenum. The endocrine portion of the gland secretes insulin vital to the control of sugar metabolism in the body through small, scattered clumps of cells known as *islets of Langerhans*. Because it contains sodium bicarbonate, pancreatic juice is alkaline, or base, with a pH of 8. Enzymes released by the pancreas act upon all types of foods, making its secretions the most important to digestion. Its enzymes include pancreatic amylase, or carbohydrate enzymes; pancreatic lipase, or fat enzymes; trypsin, or protein enzymes; and nuclease, or nucleic acid enzymes.

The most commonly known pancreatic disease is called diabetes mellitus, or sugar diabetes, which occurs when the islets of Langerhans cease producing insulin. Without insulin, the body can't use sugar, which builds up in the blood and is excreted by the kidneys.

Large intestine

After chyme works its way through the small intestine, it then must move through 5 feet or so of large intestine. The byproduct of the small intestine's work enters at the *ileocecal valve* and then moves through the following regions of the large intestine:

Cecum → Vermiform appendix → Ascending colon → Transverse colon →
Descending colon → Sigmoid colon → Rectum → Anus

The large intestine is about 3 inches wide at the start and decreases in width all the way to the anus. As the unabsorbed material moves through the large intestine, excess water is reabsorbed, drying out the material. In fact, most of the body's water absorption takes place in the large intestine. Peristaltic movement continues, albeit rather feebly, in the cecum and ascending colon. The large intestine has a longitudinal muscle layer in the form of three bands running from the cecum to the rectum called the *taenia coli*. The large intestine serves no digestive function and secretes only mucus. It has no villi, nor does it have any intestinal glands. Truly, it is the end of the line.

That's a lot of material to digest. See how much you remember:

57. Which of the following terms doesn't belong?
- Enterokinase
 - Maltose
 - Amylase
 - Sucrase
 - Erepsin
58. The parietal cells of the gastric glands secrete
- HCl
 - Pepsinogen
 - Trypsinogen
 - Pepsin
 - Mucous
59. The liver is *least* likely to be involved in
- Production of insulin
 - Production of bile pigments
 - Storage of vitamins and minerals
 - Removal of old blood cells
 - Formation of glycogen
60. The muscle that contracts to prevent gastric juices of the stomach from entering the esophagus is the
- Pyloric sphincter
 - Cardiac sphincter
 - Ileocecal sphincter
 - Fundic sphincter
 - Gastric sphincter

- 61.** The organ in which most digestion occurs is the
- Mouth
 - Stomach
 - Esophagus
 - Large intestine
 - Small intestine
- 62.** The enzyme found in the intestinal juices that activates the pancreatic enzyme into an active enzyme that can break down protein is called
- Maltase
 - Proteolytic enzyme
 - Erepsin
 - Inverting enzyme
 - Enterokinase
- 63.** What structure of the small intestine is composed of a network of capillaries with a central lymph vessel or lacteal, which contains a milky-white substance?
- Rugae
 - Villi
 - Paneth cells
 - Islets of Langerhans
 - Plicae circularis
- 64.** Microscopically, the liver is composed of rows of cuboidal cells with small blood spaces running between the cells called
- Sinusoids
 - Cubisoids
 - Freakasoids
 - Rugae
 - Biliary canaliculi