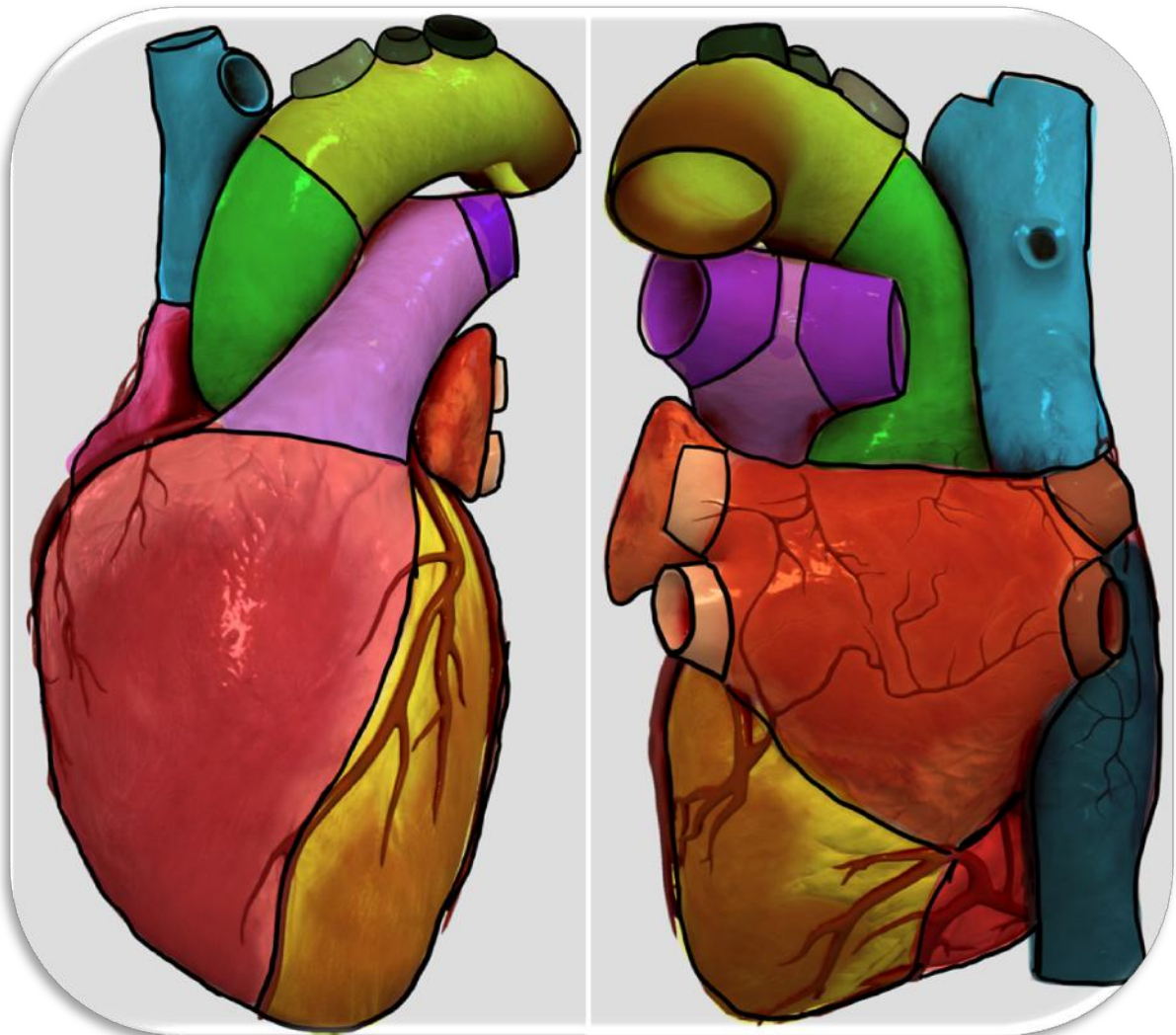
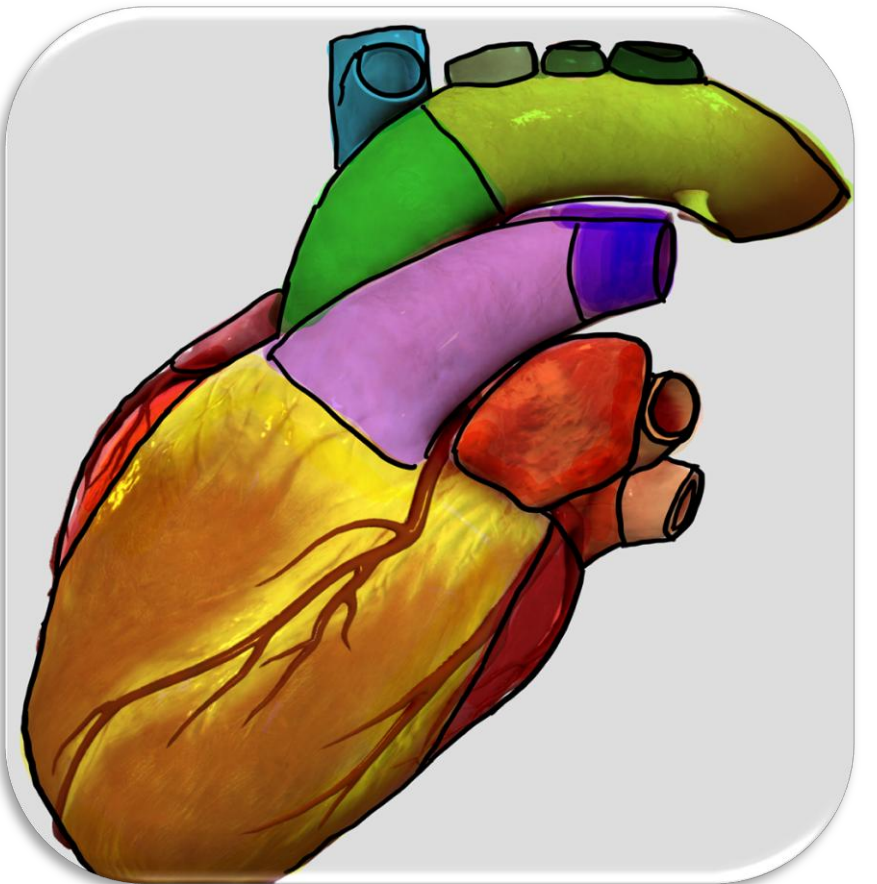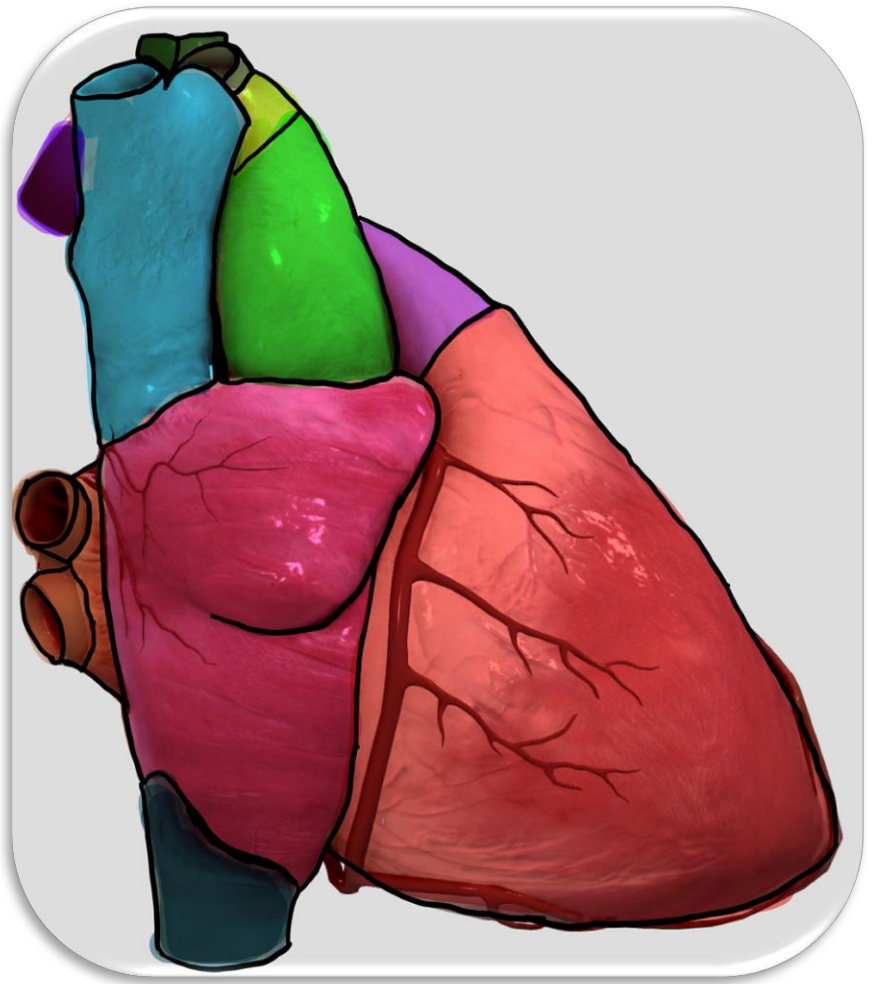


Structures of the Heart

Aortic Arch	Aortic Semi-Lunar Valve	Apex of Heart	Ascending Aorta
Atrium (L)	Atrium (R)	Atrial Appendage (L)	Atrioventricular Valve (L)
Atrioventricular Valve (R)	A-V Valve (L)	A-V Valve (R)	Bicuspid Valve
Brachiocephalic Artery	Chordae Tendineae	Coronary Artery	Common Carotid Artery (L)
Descending Aorta	Inferior Vena Cava	Mitral Valve	Pulmonary Arteries (L)
Pulmonary Arteries (R)	Pulmonary Semi-Lunar Valve	Pulmonary Trunk	Pulmonary Veins (L)
Pulmonary Veins (R)	Septum of Heart	Subclavian Artery (L)	Superior Vena Cava
Thoracic Aorta	Tricuspid Valve	Ventricle (L)	Ventricle (R)



Color	Structure(s)
Blue	
Pink	
Red	
Purple	
Orange	
Yellow	
Green	



Structure(s)

Color

Blue

Pink

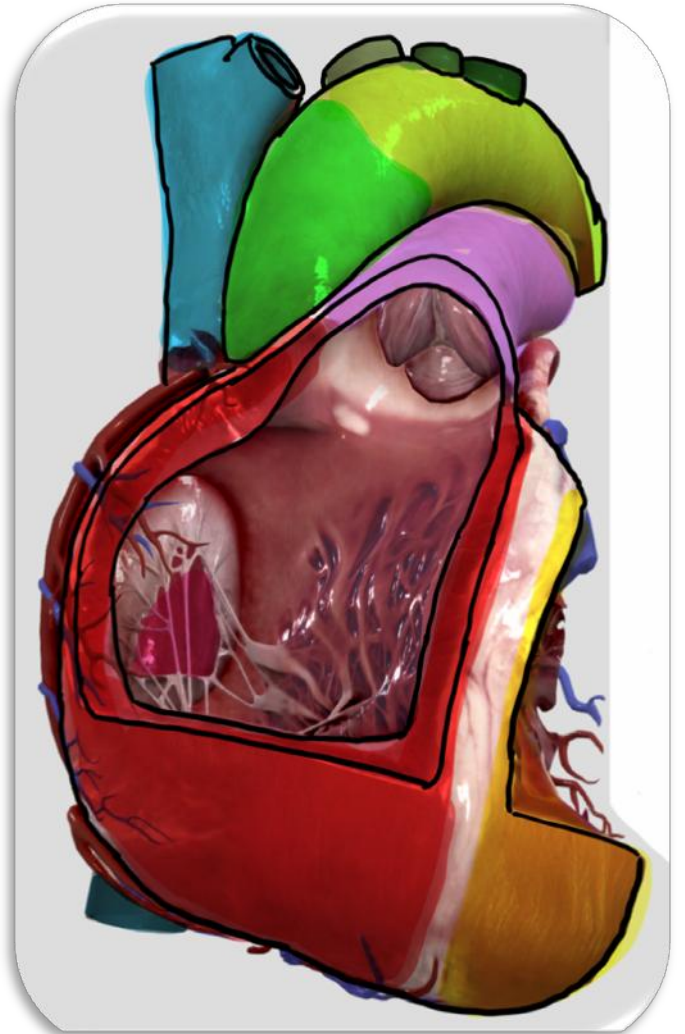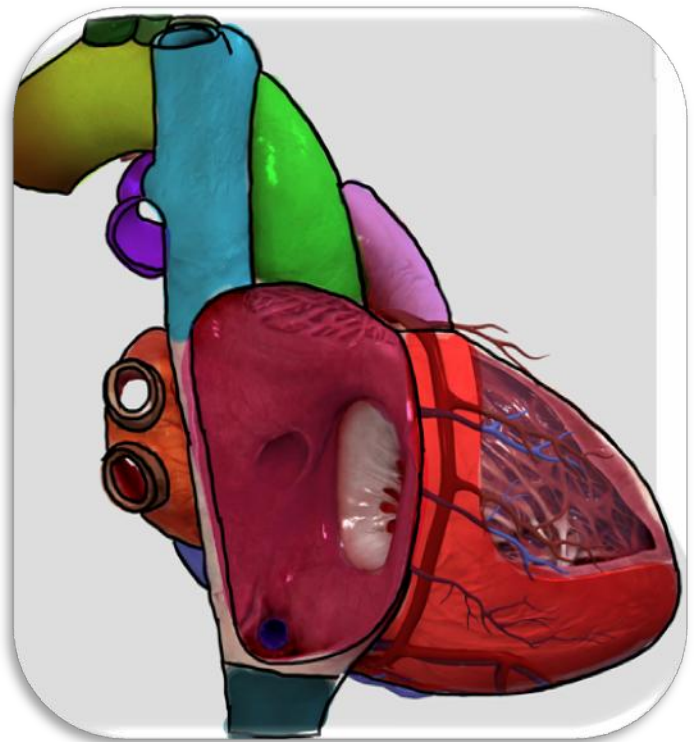Red

Purple

Orange

Yellow

Green



Color	Structure(s)
Blue	
Pink	
Red	
Purple	
Orange	
Yellow	
Green	

