

DIGESTIVE SYSTEM

Accessory Organs
Salivary Glands, Liver, Gall Bladder,
& Pancreas

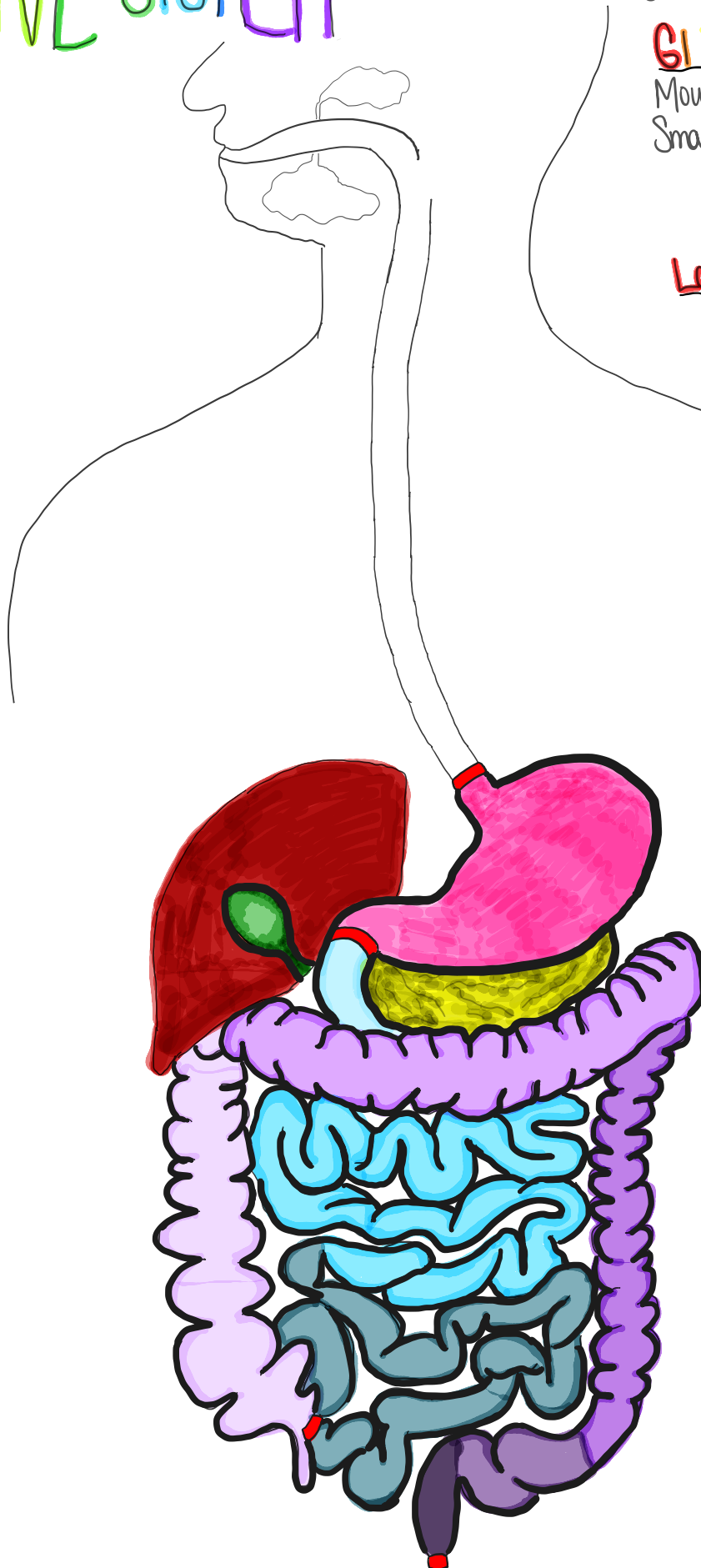
GI Tract
Mouth, Esophagus, Stomach,
Small Intestine

- 1) duodenum
- 2) jejunum
- 3) ileum

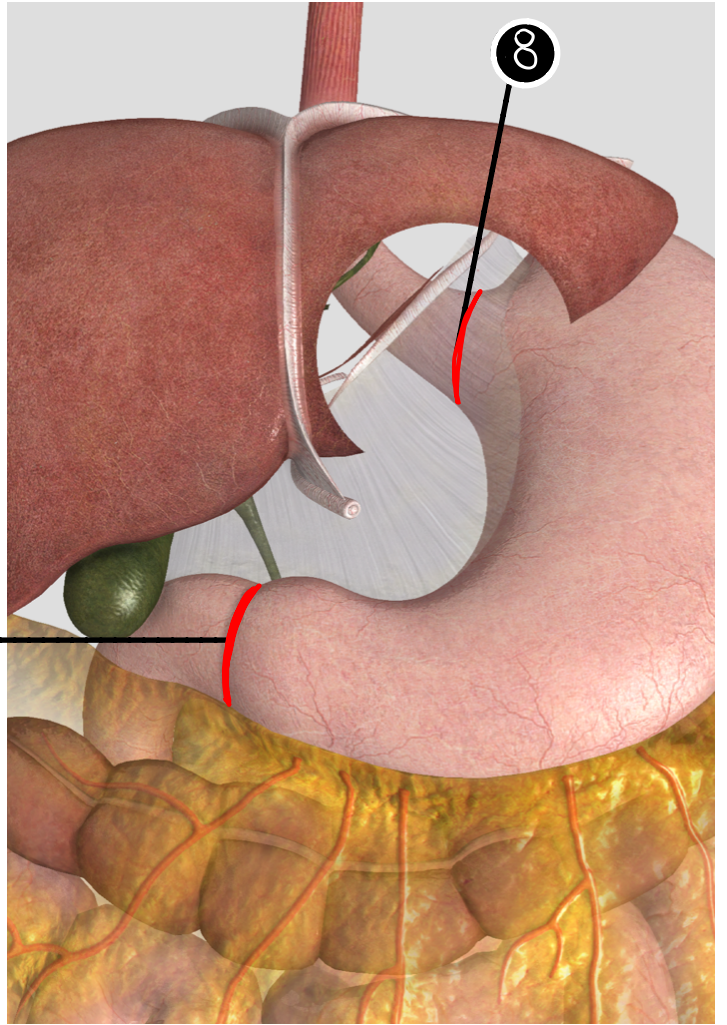
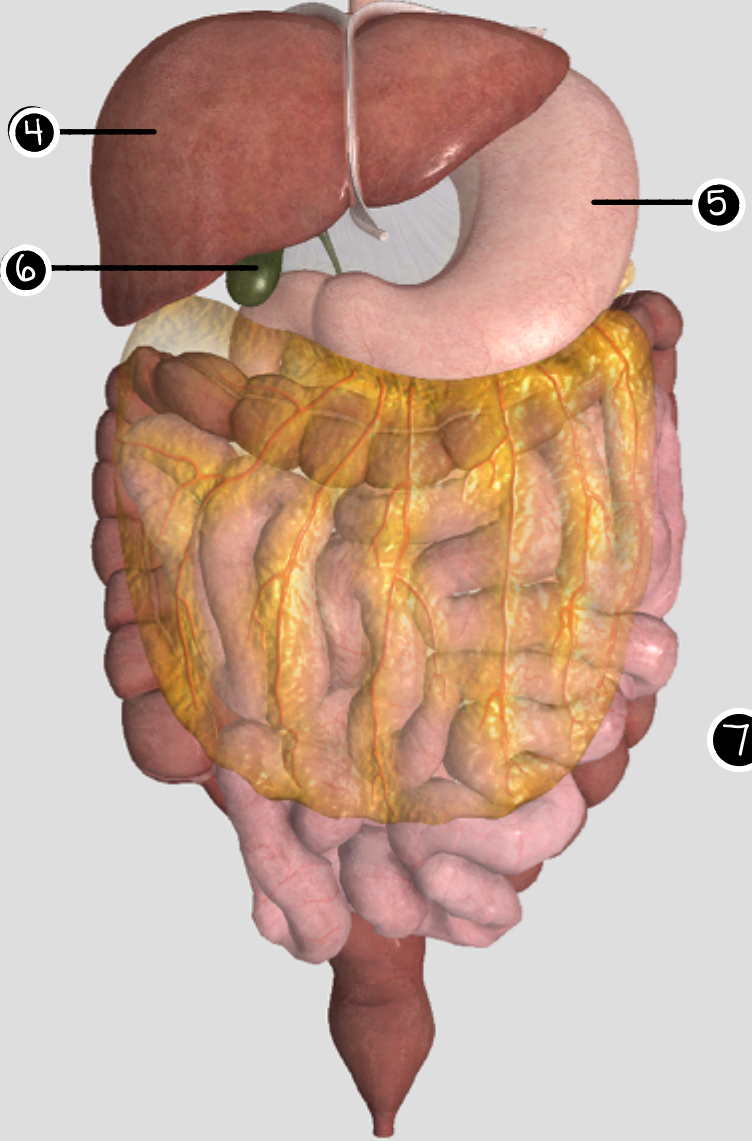
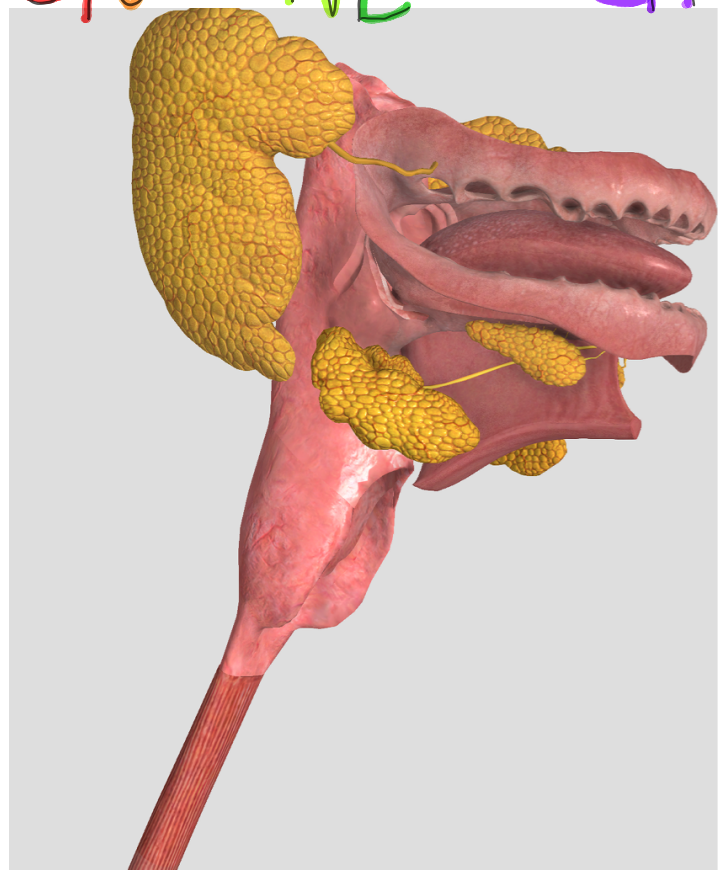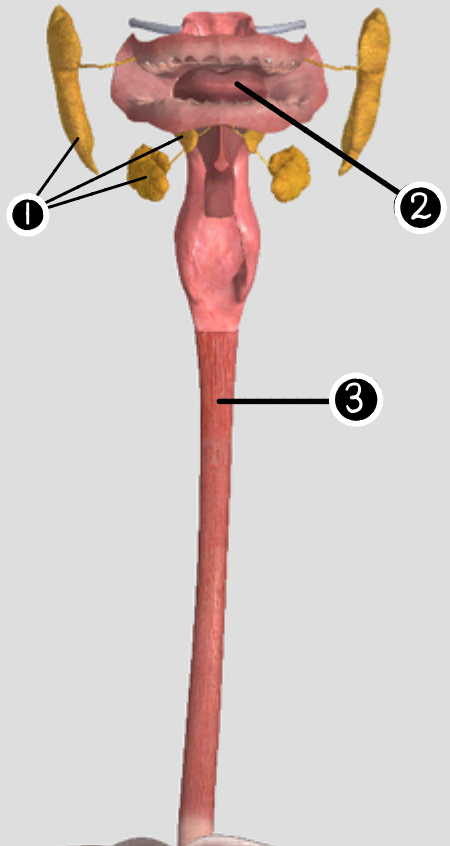
Large Intestine

- 1) ascending colon (appendix)
- 2) transverse colon
- 3) descending colon
- 4) sigmoid colon
- 5) rectum

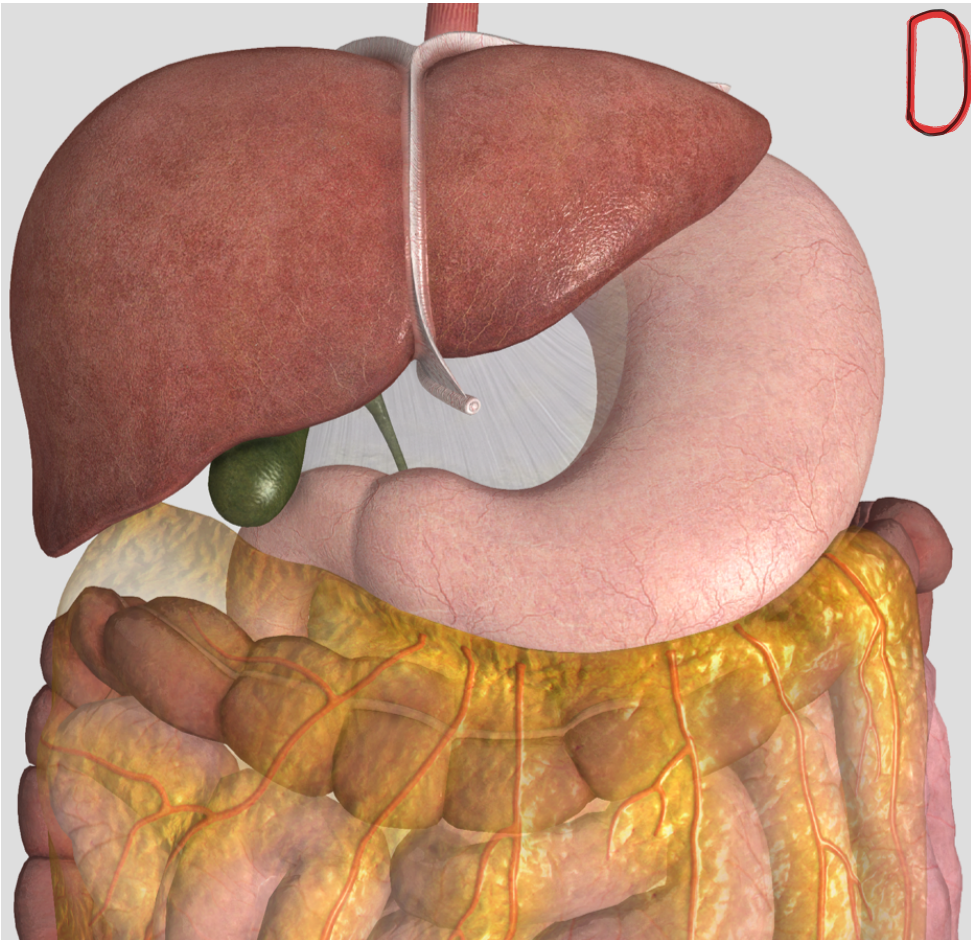
Sphincters
Cardioesophageal
pyloric
ileocecal
internal anal
external anal



DIGESTIVE SYSTEM

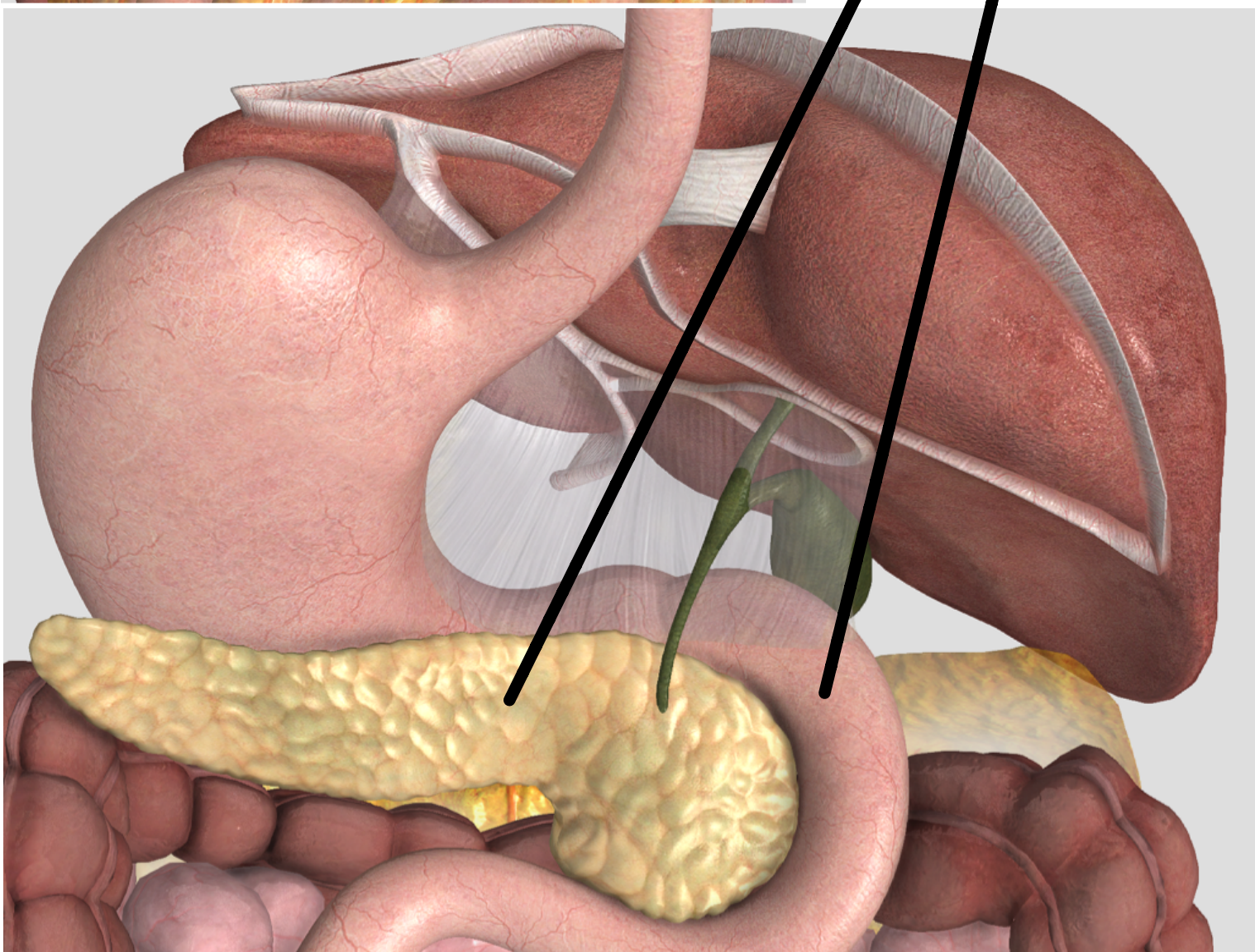


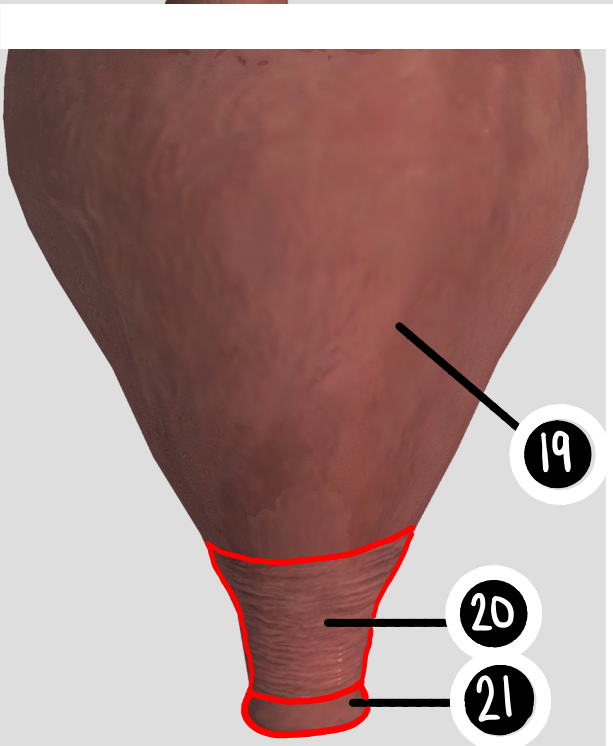
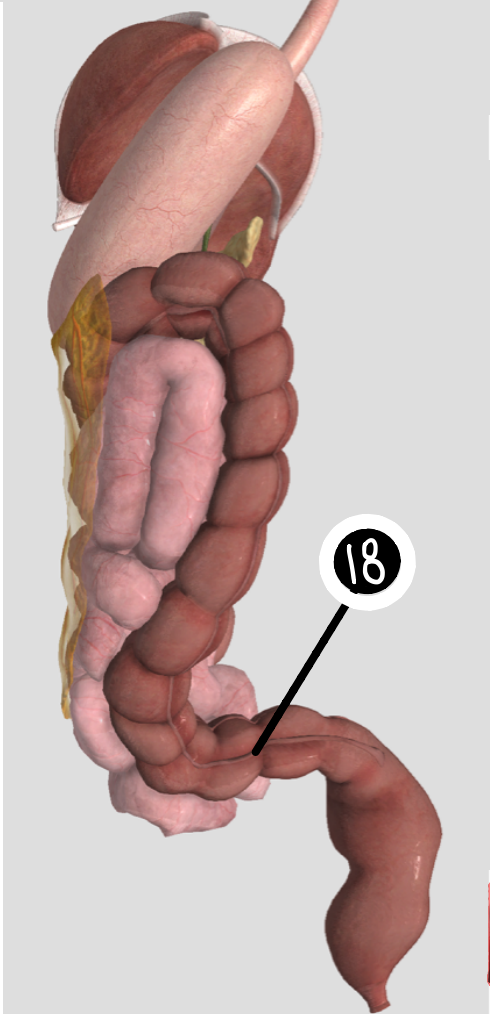
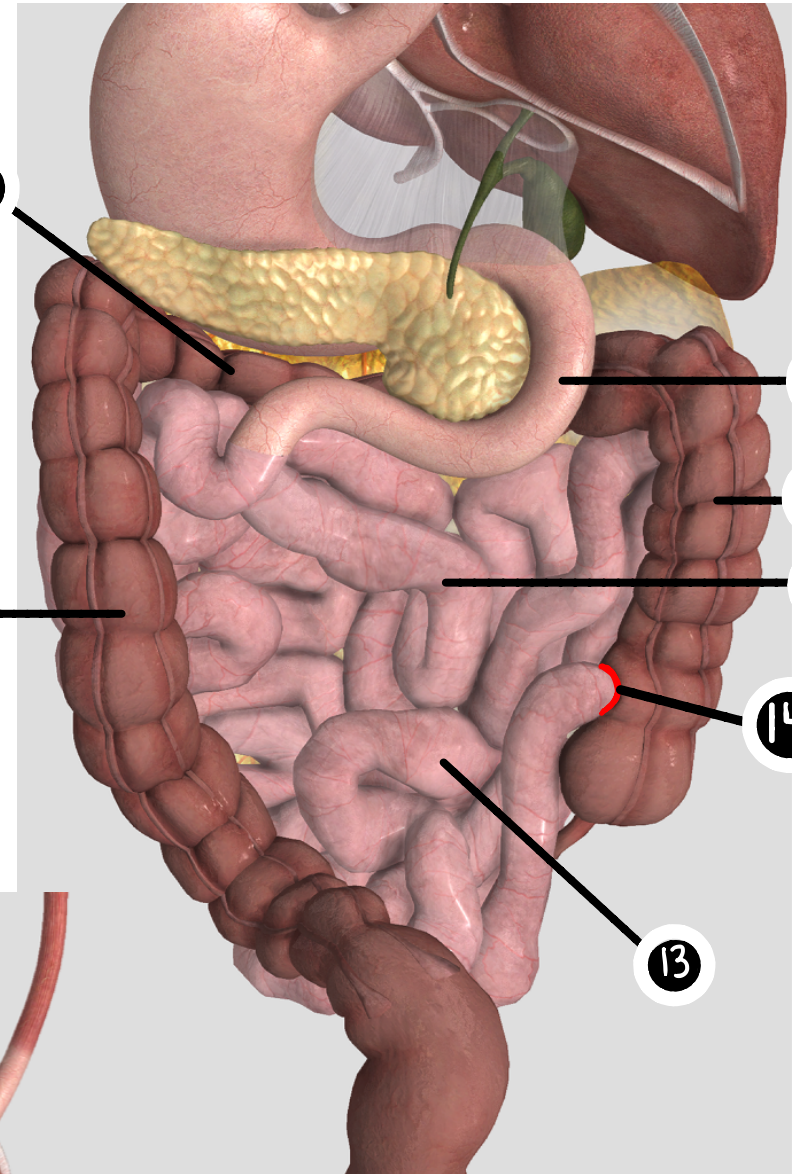
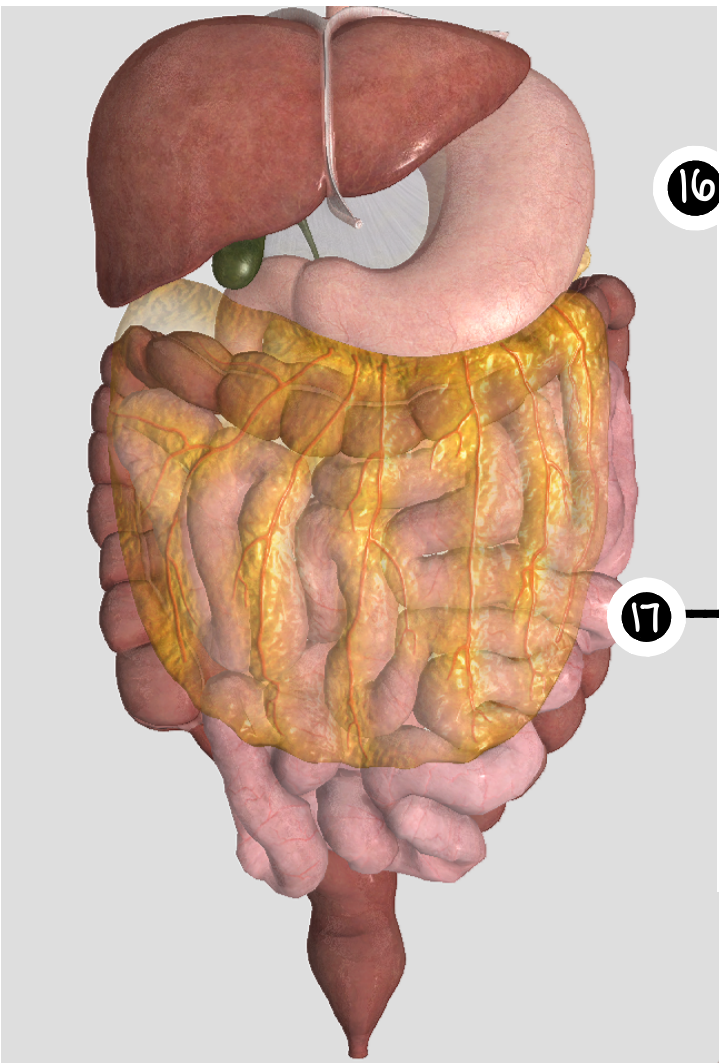
DIGESTIVE SYSTEM



9

10





DIGESTIVE SYSTEM

DIGESTIVE SYSTEM

