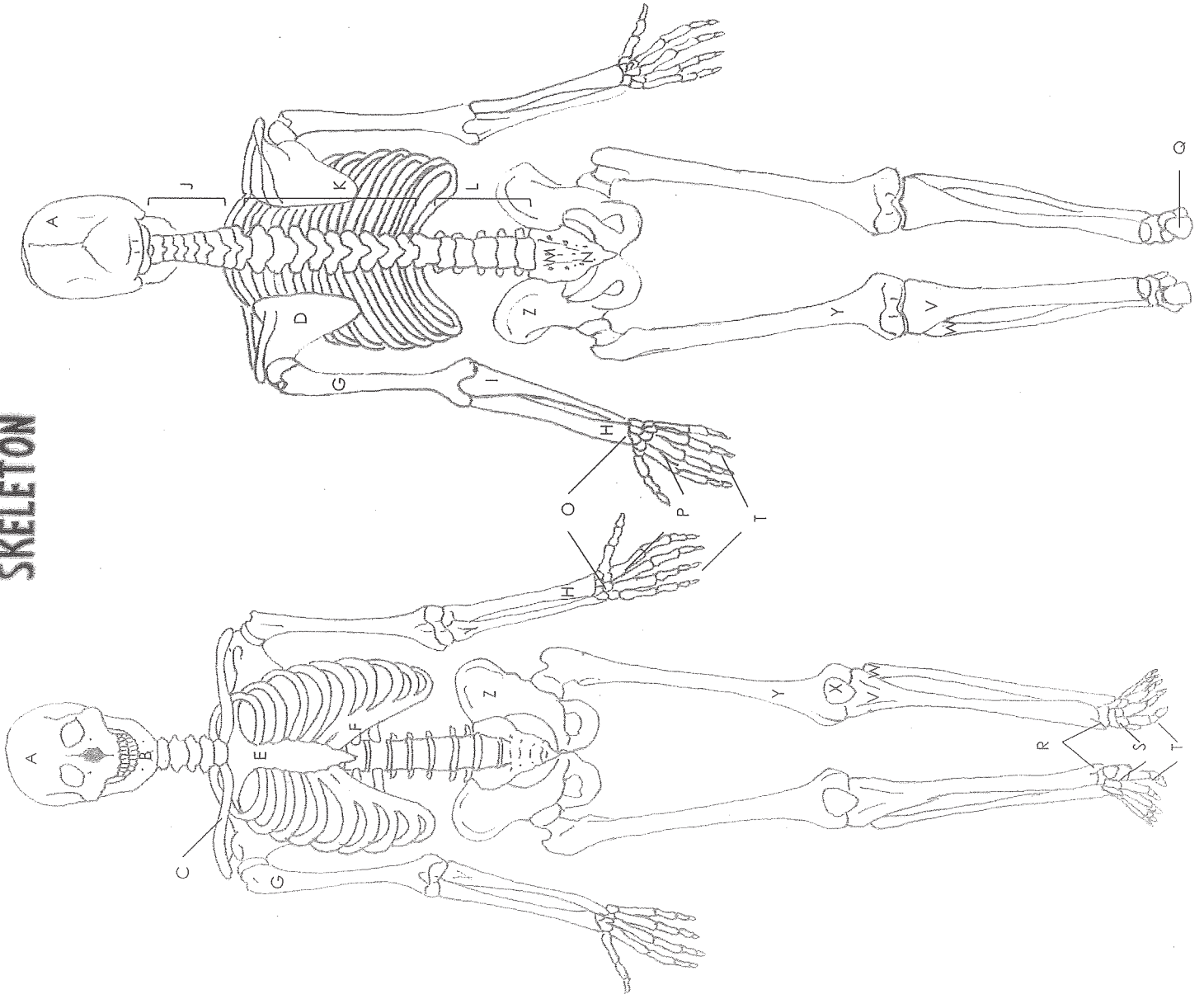


SKELETON



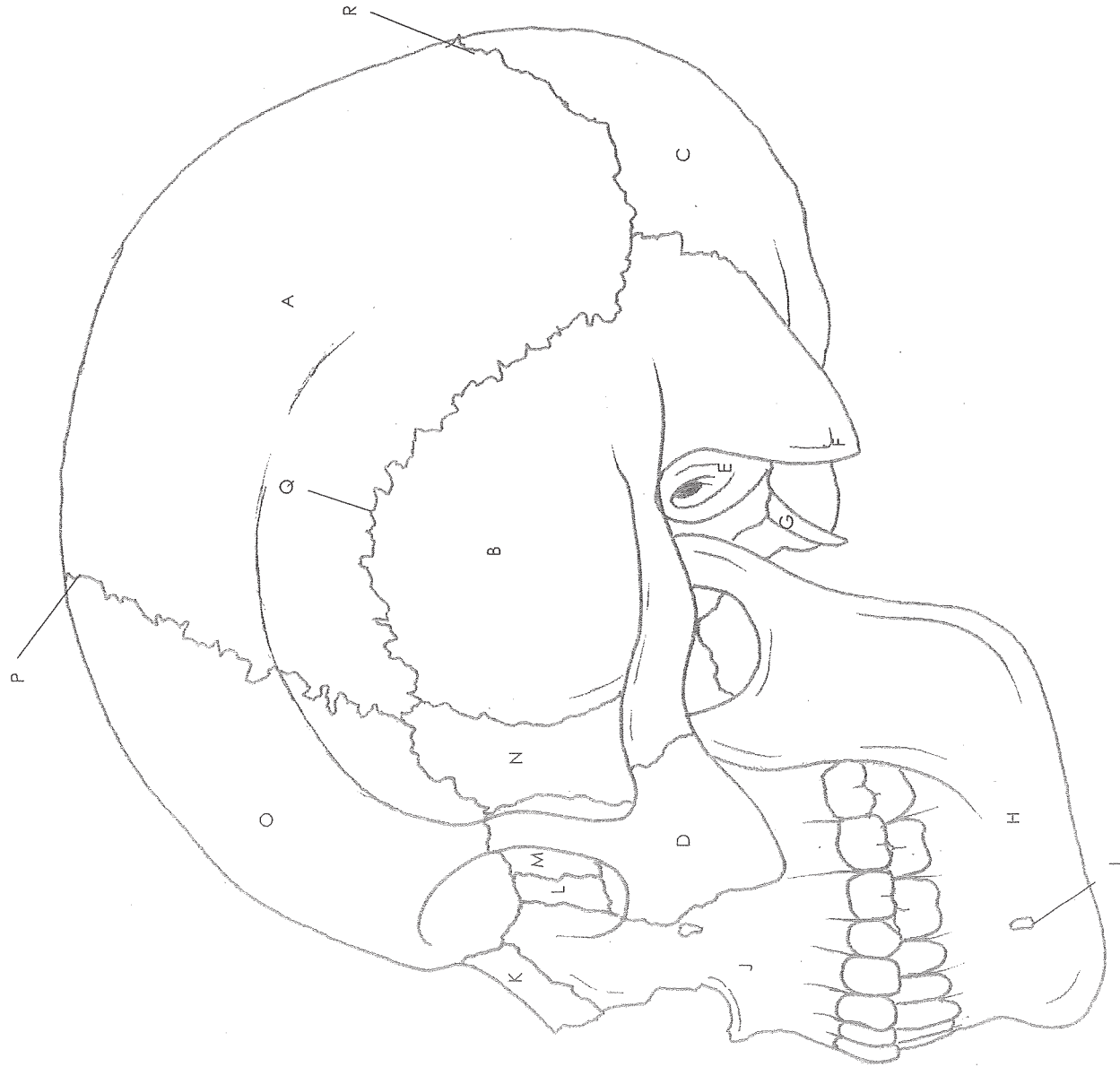Name: _____

Date: _____ Period: _____

Answer Key

- A. Skull
- B. Mandible
- C. Clavicle
- D. Scapula
- E. Sternum
- F. Ribs
- G. Humerus
- H. Radius
- I. Ulna
- J. Cervical vertebrae
- K. Thoracic vertebrae
- L. Lumbar vertebrae
- M. Sacrum
- N. Coccyx
- O. Carpals
- P. Metacarpals
- Q. Calcaneus
- R. Tarsals
- S. Metatarsals
- T. Phalanges
- V. Tibia
- W. Fibula
- X. Patella
- Y. Femur
- Z. Pelvis

SKULL Lateral View



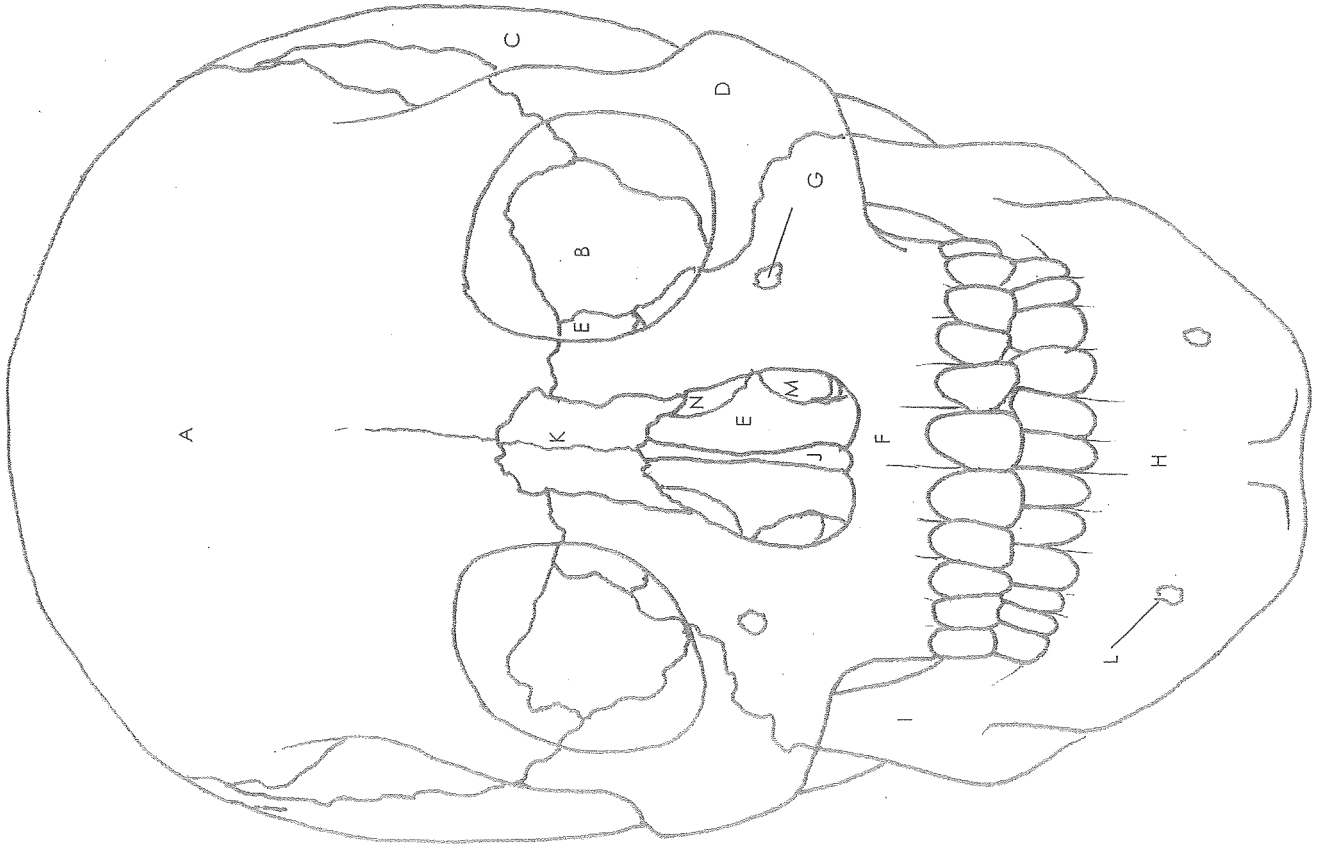
Name: _____

Date: _____ Period: _____

Answer Key

- A. Parietal bone
- B. Temporal bone
- C. Occipital bone
- D. Zygomatic bone
- E. External acoustic meatus
- F. Mastoid process
- G. Styloid process
- H. Mandible
- I. Mental foramen
- J. Maxilla
- K. Nasal bone
- L. Lacrimal bone
- M. Ethmoid bone
- N. Sphenoid bone
- O. Frontal bone
- P. Coronal suture
- Q. Squamous suture
- R. Lambdoid suture

SKULL Frontal View



Name: _____

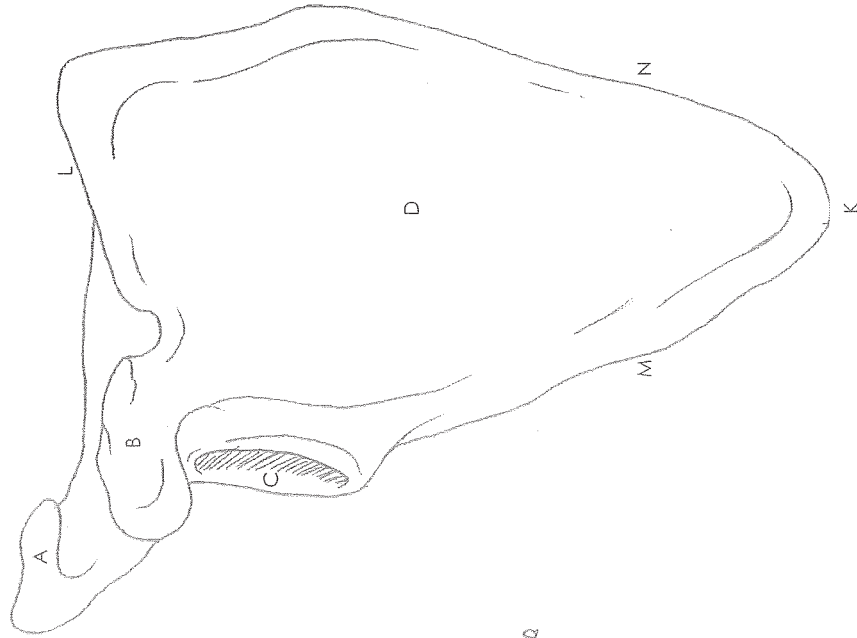
Date: _____ Period: _____

Answer Key

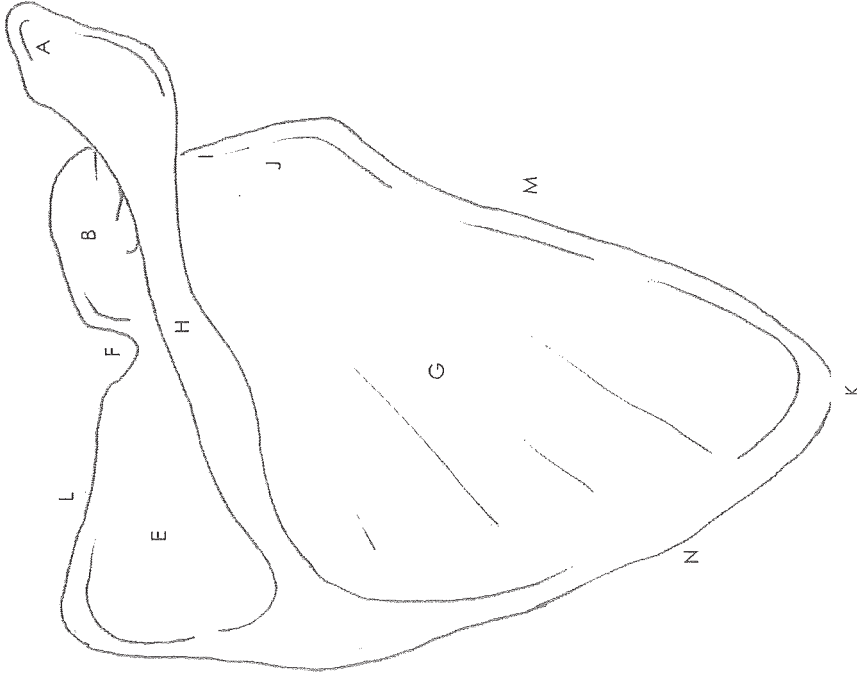
- A. Frontal bone
- B. Sphenoid bone
- C. Temporal bone
- D. Zygomatic bone
- E. Ethmoid bone
- F. Maxilla
- G. Infraorbital foramen
- H. Mandible
- I. Ramus
- J. Vomer
- K. Nasal bone
- L. Mental foramen
- M. Inferior nasal concha
- N. Middle nasal concha

SCAPULA

Anterior



Posterior



Name: _____

Date: _____ Period: _____

Answer Key

- A. Acromion
- B. Coracoid process
- C. Glenoid cavity
- D. Subscapular fossa
- E. Supraspinous fossa
- F. Suprascapular notch
- G. Infraspinous fossa
- H. Spine
- I. Scapula head
- J. Scapula neck
- K. Inferior angle
- L. Superior border
- M. Lateral border
- N. Medial border

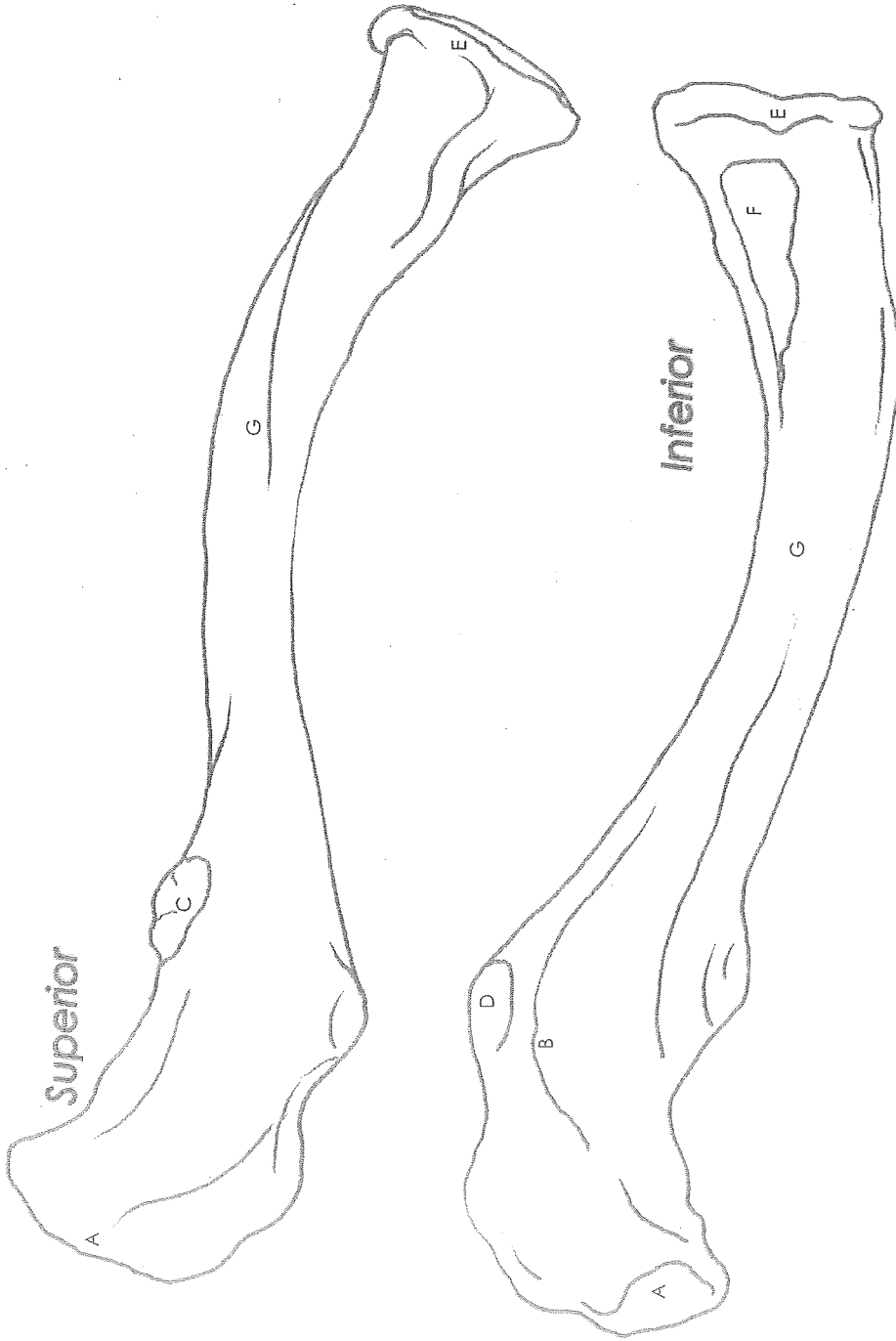
CLAVICLE

Name: _____

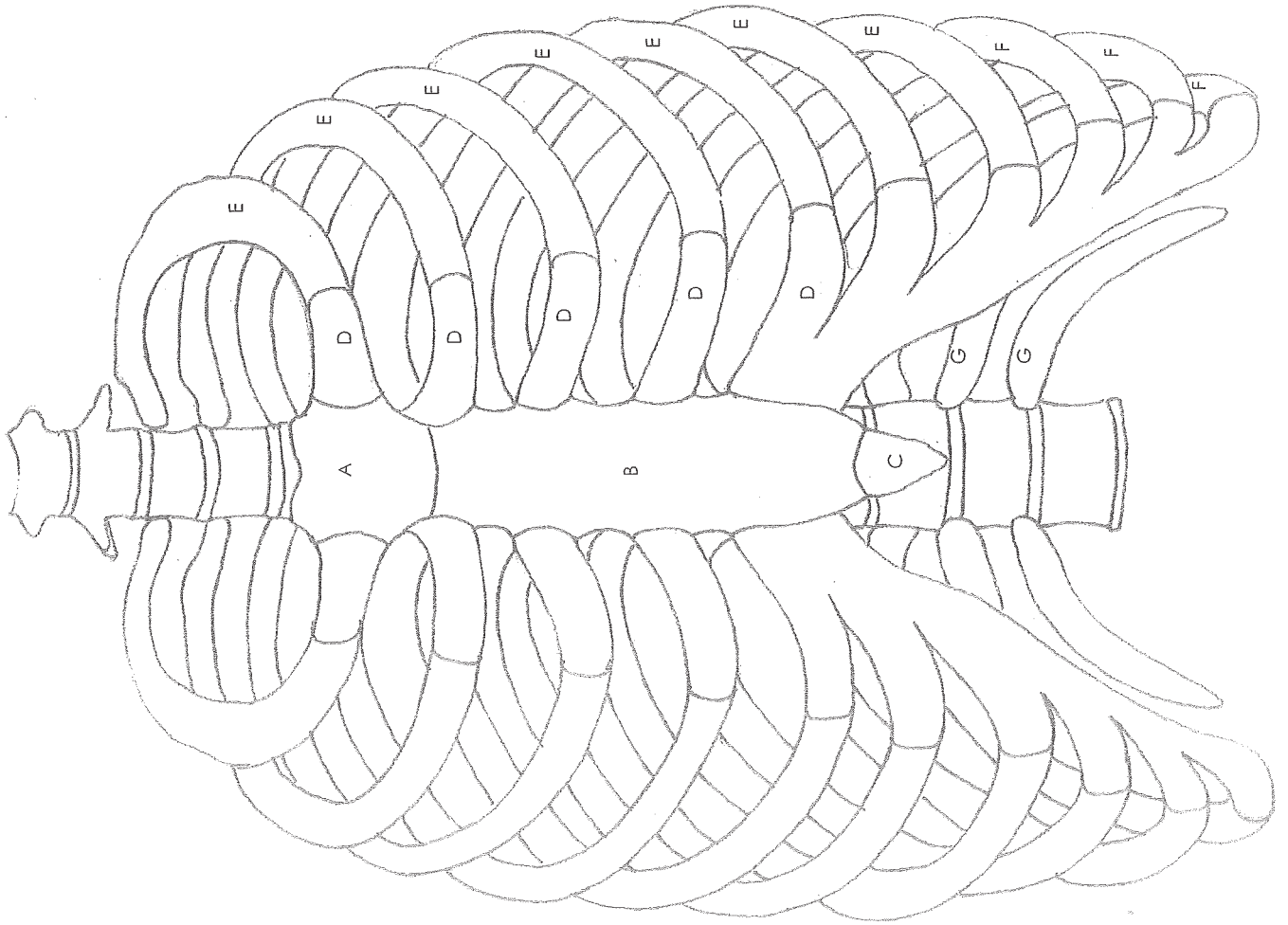
Date: _____ Period: _____

Answer Key

- A. Acromial extremity
- B. Trapezoid ridge or line
- C. Deltoid tubercle
- D. Conoid tubercle
- E. Sternal extremity
- F. Costal tuberosity
- G. Body of clavicle



RIB CAGE



Name: _____

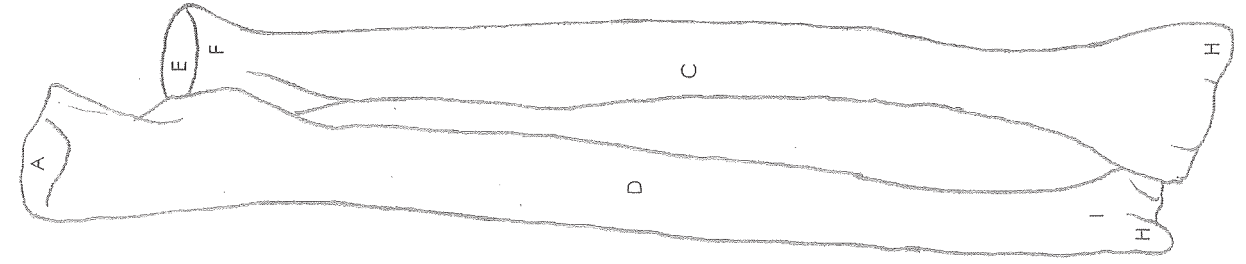
Date: _____ Period: _____

Answer Key

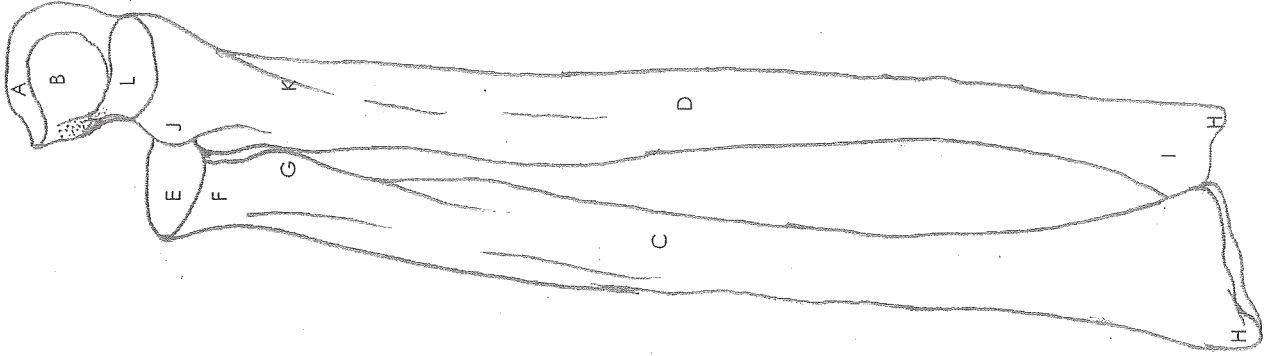
- A. Manubrium
- B. Sternum body
- C. Xiphoid process
- D. Costal cartilage
- E. True ribs
- F. False ribs
- G. Floating ribs

RADIUS & ULNA

Posterior



Anterior



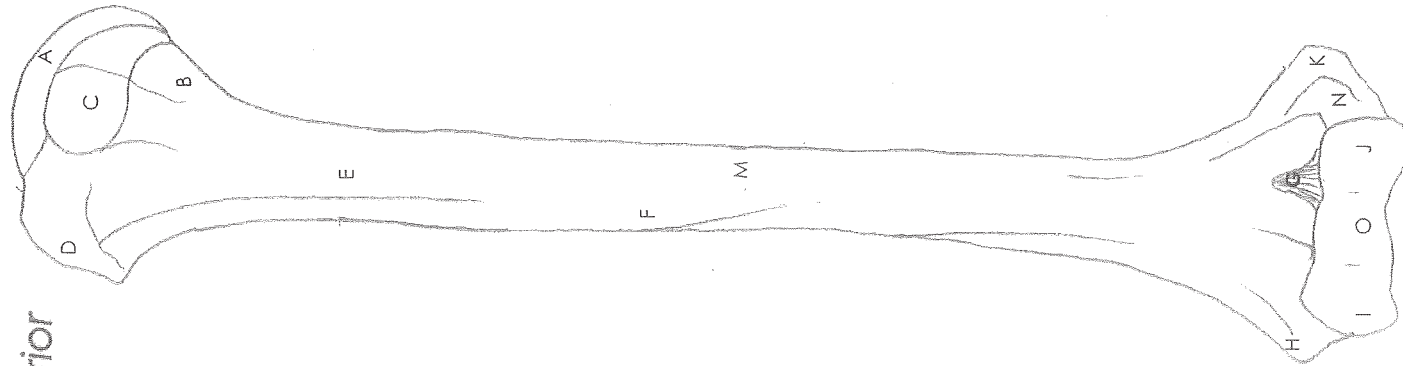
Name: _____

Date: _____ Period: _____

Answer Key

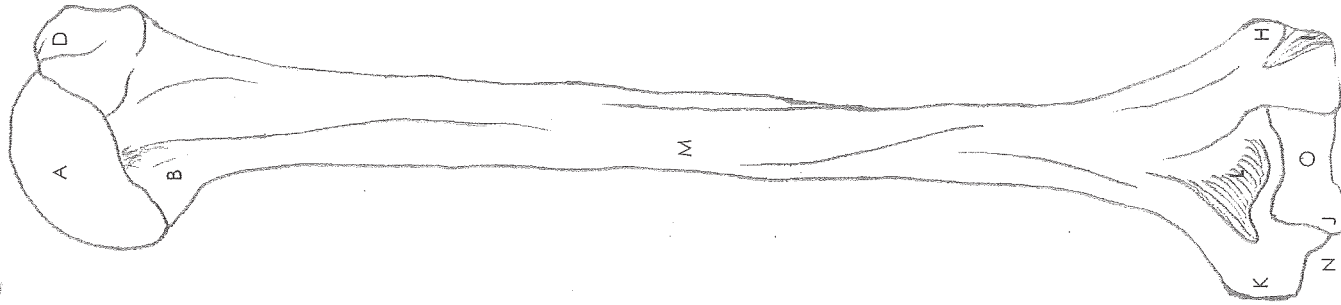
- A. Olecranon process
- B. Trochlear notch
- C. Shaft of radius
- D. Shaft of ulna
- E. Radial head
- F. Radial neck
- G. Radial tuberosity
- H. Styloid process
- I. Ulnar head
- J. Radial notch
- K. Ulnar tuberosity
- L. Coronoid process

Anterior



HUMERUS

Posterior



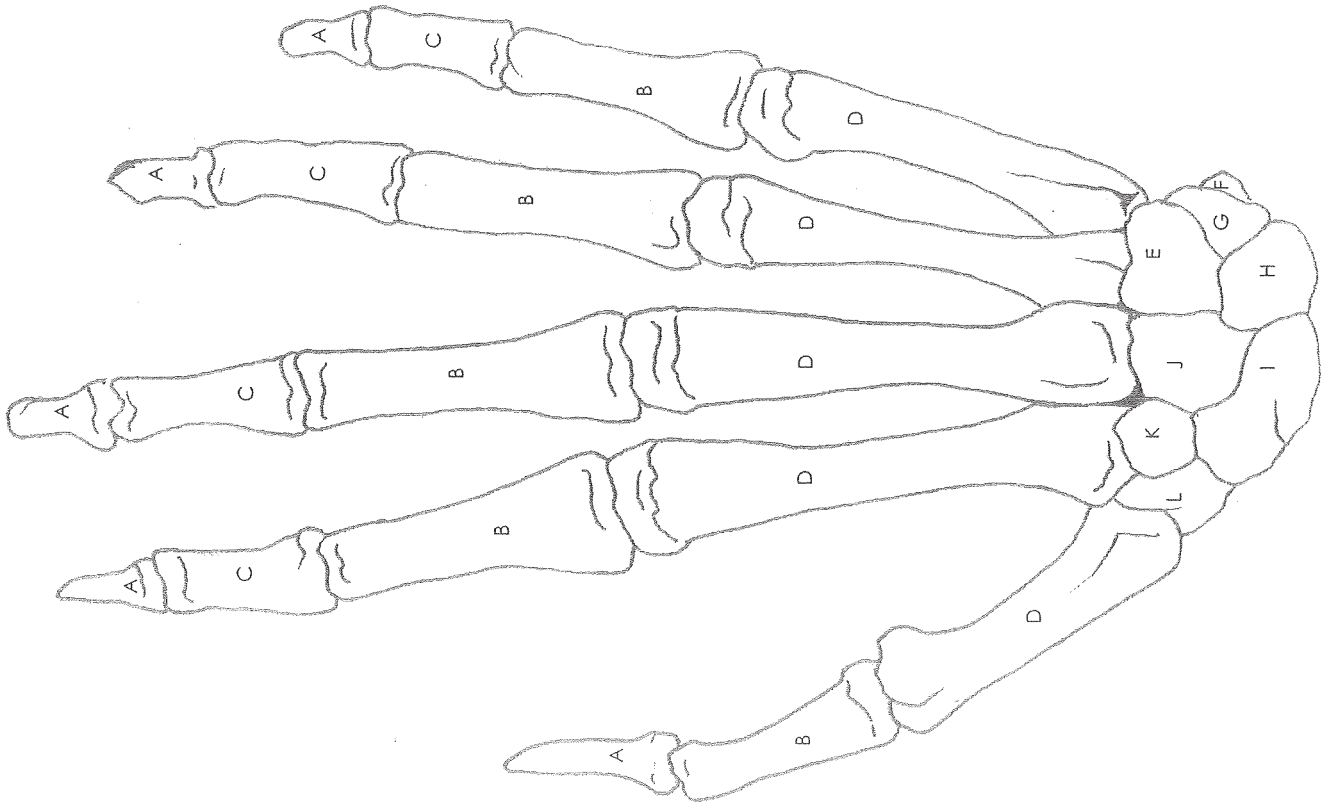
Name: _____

Date: _____ Period: _____

Answer Key

- A. Head
- B. Neck
- C. Lesser tuberosity
- D. Greater tuberosity
- E. Intertubercular groove
- F. Deltoid tuberosity
- G. Coronoid fossa
- H. Lateral epicondyle
- I. Capitulum
- J. Trochlea
- K. Medial epicondyle
- L. Olecranon fossa
- M. Shaft of humerus
- N. Ulnar groove
- O. Humeral condyle

BONES OF THE HAND



Name: _____

Date: _____ Period: _____

Answer Key

- A. Distal phalanges
- B. Proximal phalanges
- C. Middle phalanges
- D. Metacarpals
- E. Hamate
- F. Pisiform
- G. Triquetrum
- H. Lunate
- I. Scaphoid
- J. Capitate
- K. Trapezoid
- L. Trapezium

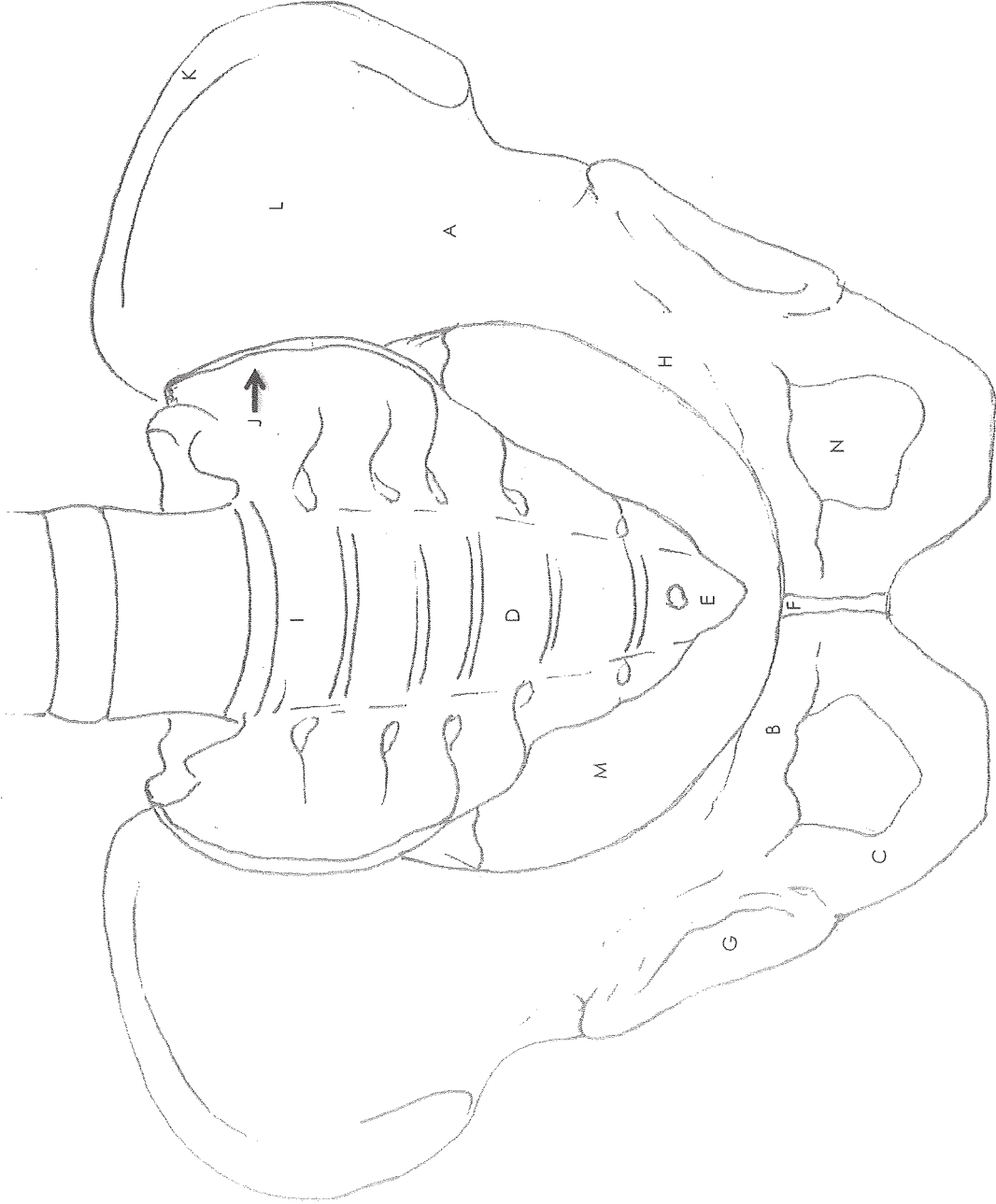
PELVIS

Name: _____

Date: _____ Period: _____

Answer Key

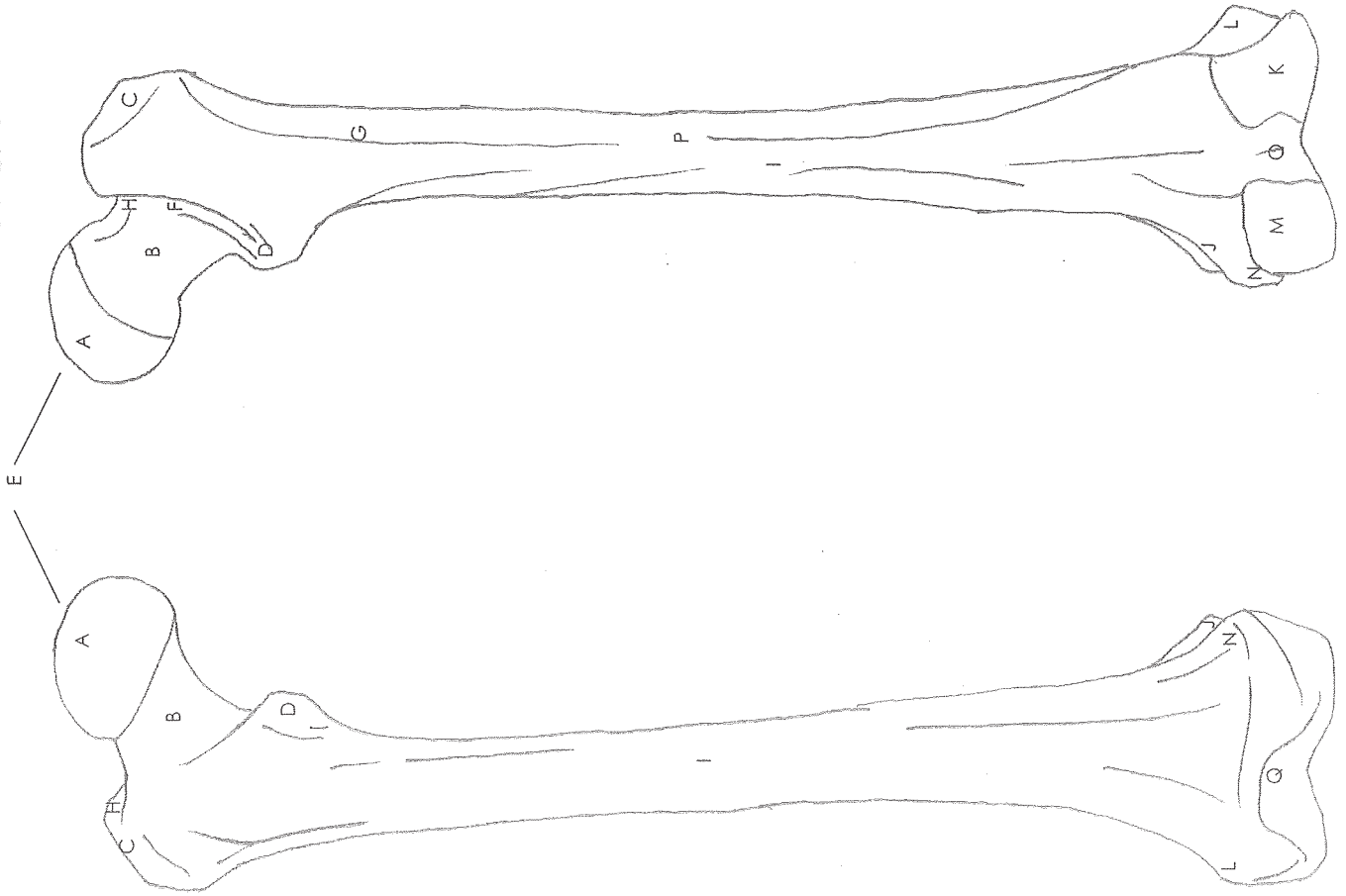
- A. Ilium
- B. Pubis
- C. Ischium
- D. Sacrum
- E. Coccyx
- F. Pubic symphysis
- G. Acetabulum
- H. Ischial spine
- I. Sacral promontory
- J. Sacroiliac joint
- K. Iliac crest
- L. Iliac fossa
- M. Pelvic inlet
- N. Obturator foramen



FEMUR

Anterior

Posterior



Name: _____

Date: _____ Period: _____

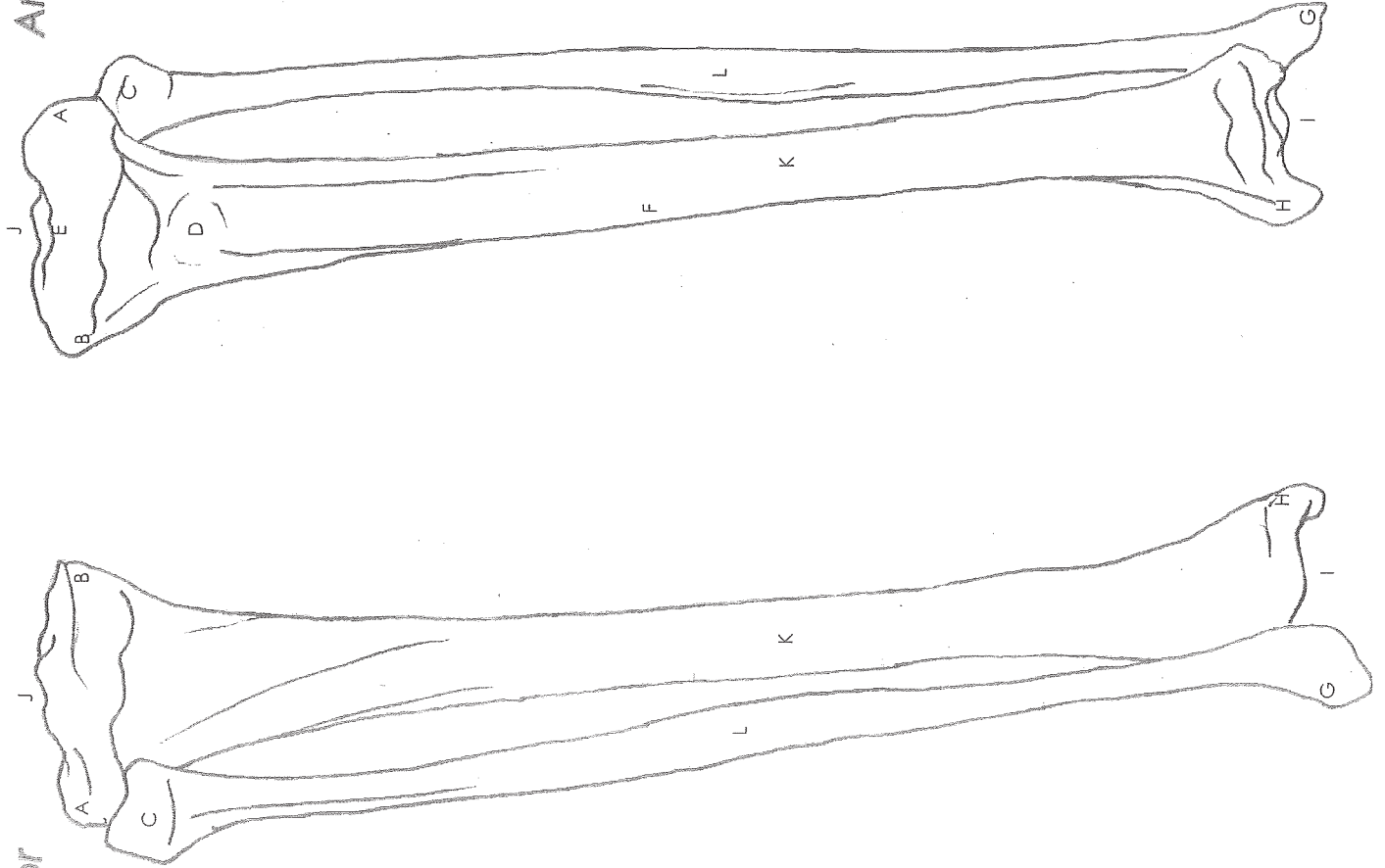
Answer Key

- A. Head
- B. Neck
- C. Greater trochanter
- D. Lesser trochanter
- E. Fovea capitis
- F. Intertrochanteric crest
- G. Gluteal tuberosity
- H. Trochanteric fossa
- I. Shaft
- J. Adductor tubercle
- K. Lateral condyle
- L. Lateral epicondyle
- M. Medial condyle
- N. Medial epicondyle
- O. Intercondylar fossa
- P. Linea aspera
- Q. Patellar surface

TIBIA & FIBULA

Posterior

Anterior



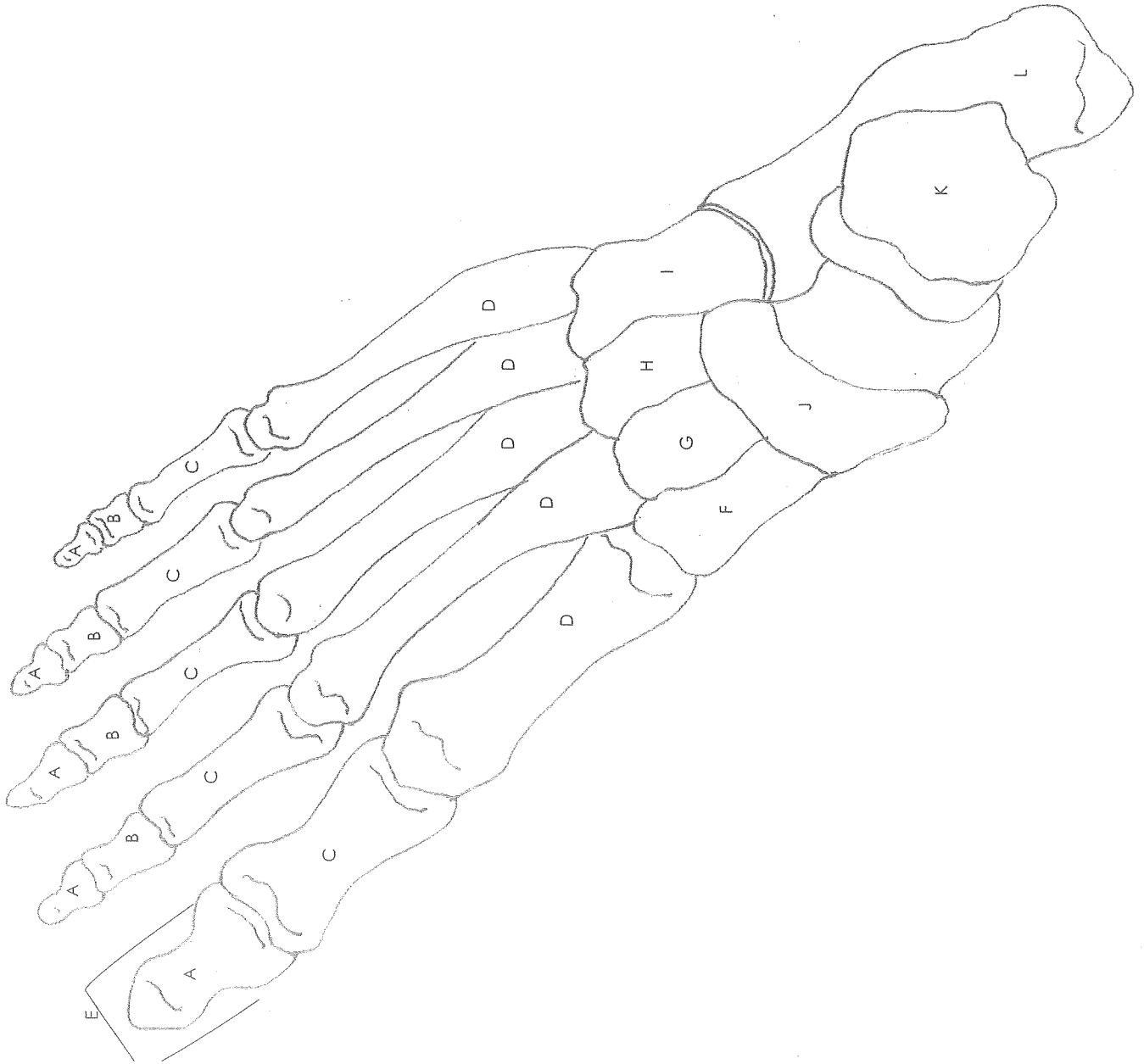
Name: _____

Date: _____ Period: _____

Answer Key

- A. Lateral condyle
- B. Medial condyle
- C. Fibula head
- D. Tibial tuberosity
- E. Intercondylar eminence
- F. Anterior crest
- G. Lateral malleolus
- H. Medial malleolus
- I. Inferior articular surface
- J. Superior articular surface
- K. Tibia body
- L. Fibula body

BONES OF THE FOOT



Name: _____

Date: _____ Period: _____

Answer Key

- A. Distal phalanges
- B. Middle phalanges
- C. Proximal phalanges
- D. Metatarsals
- E. Hallux
- F. Medial cuneiform
- G. Intermediate cuneiform
- H. Lateral cuneiform
- I. Cuboid
- J. Navicular
- K. Talus
- L. Calcaneus