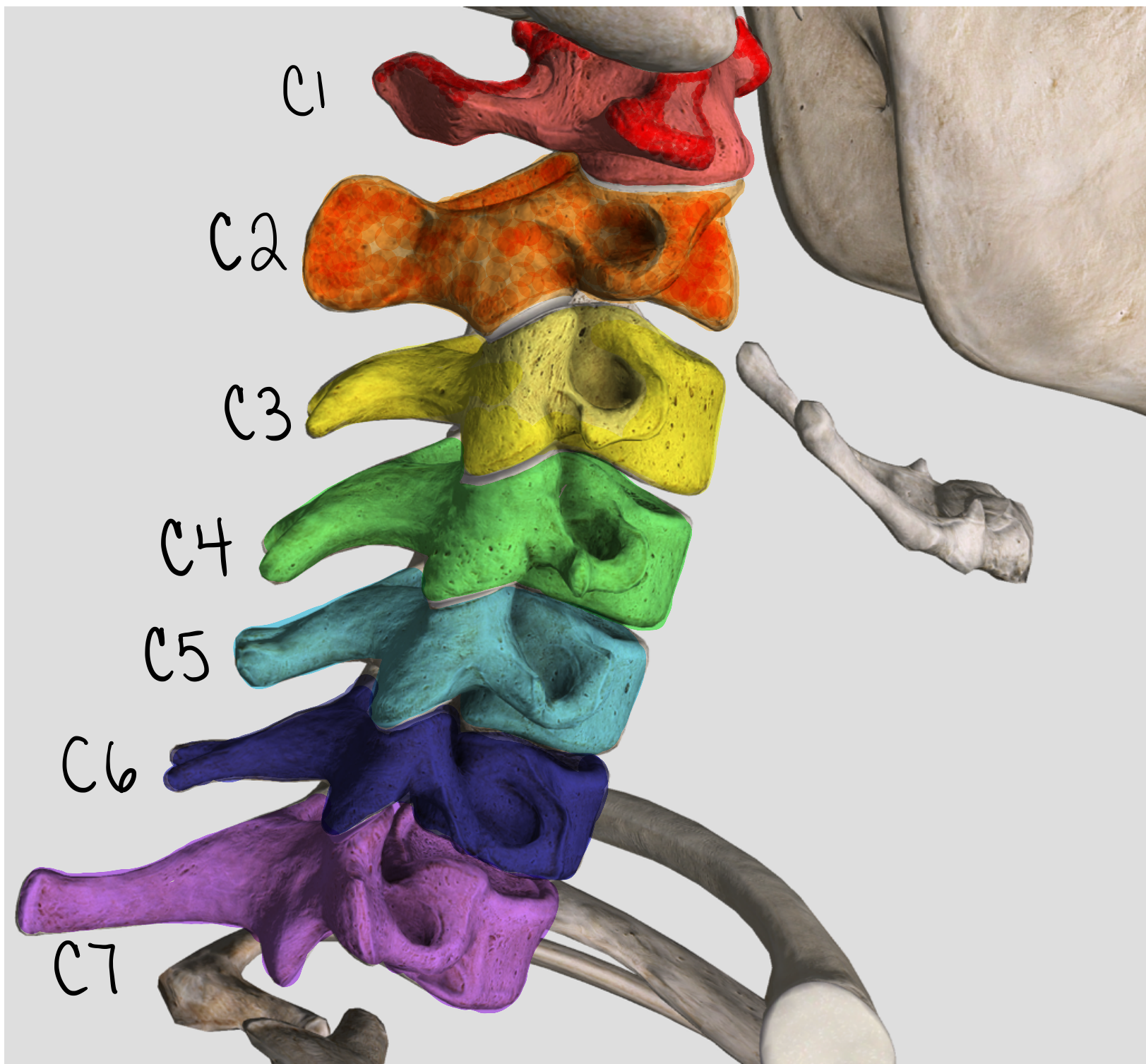


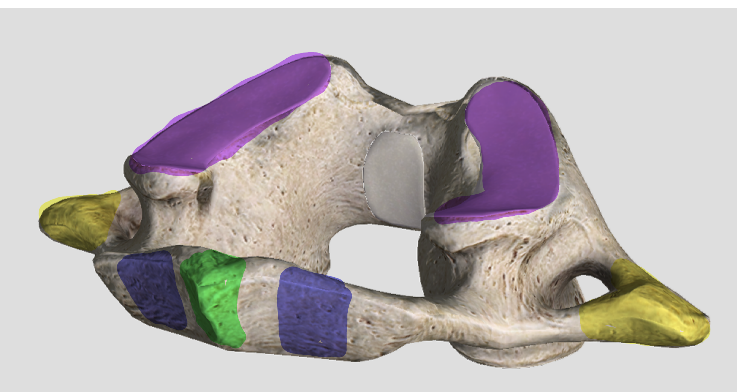
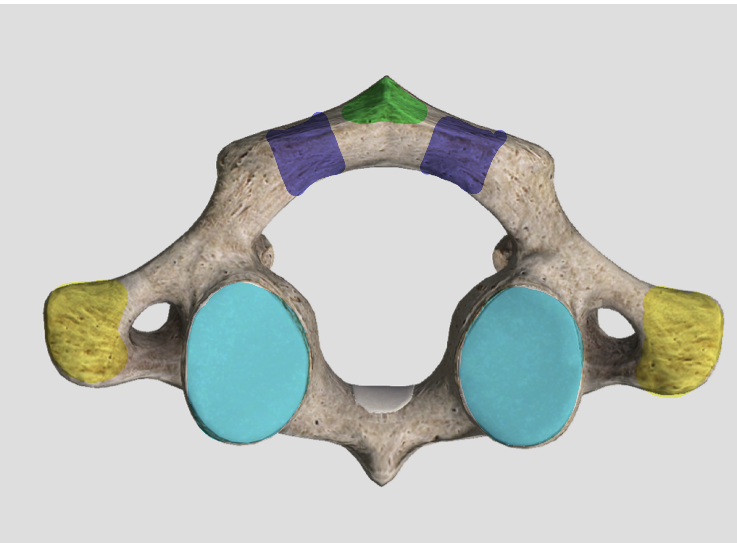
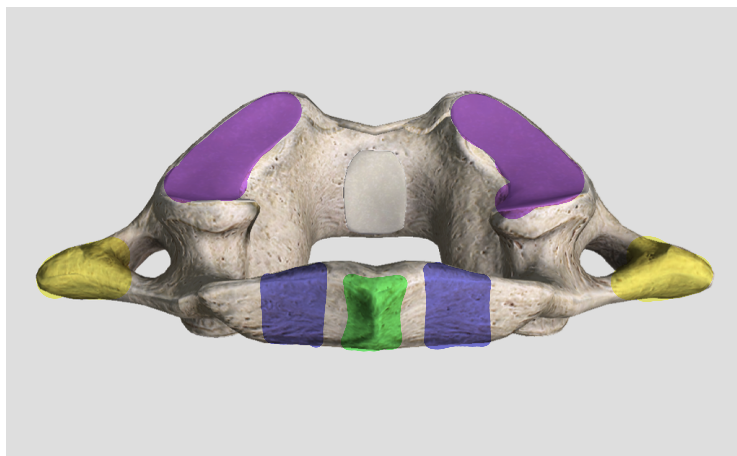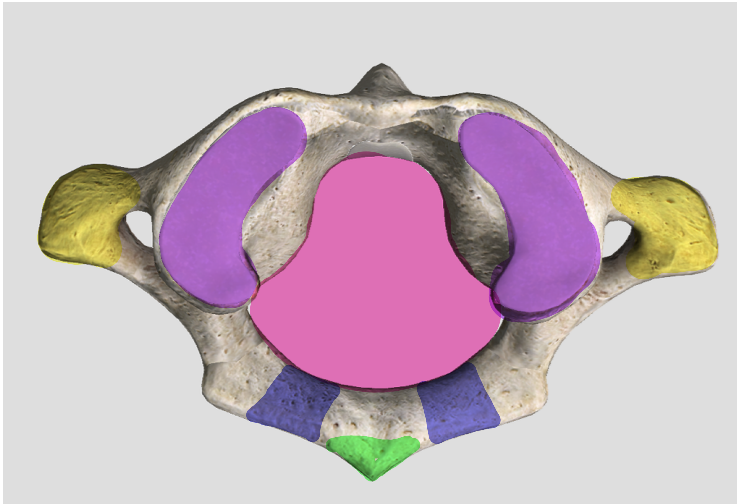
Axial Spine

Cervical Vertebra
#14

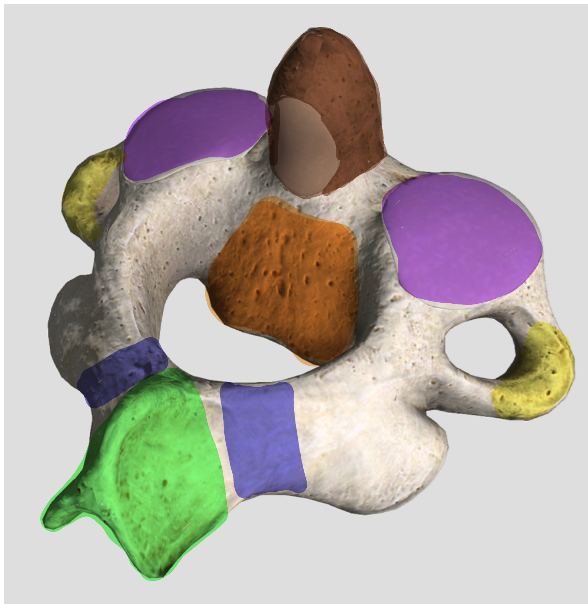
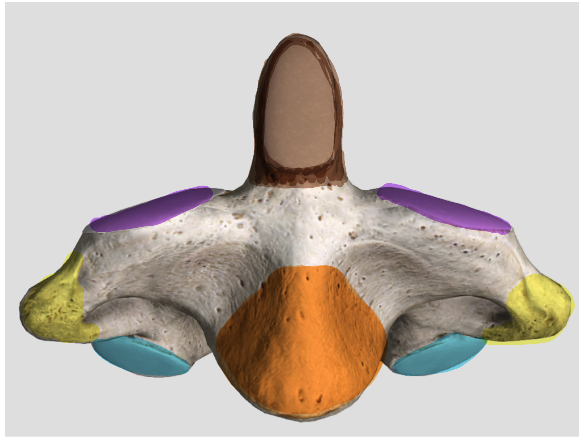
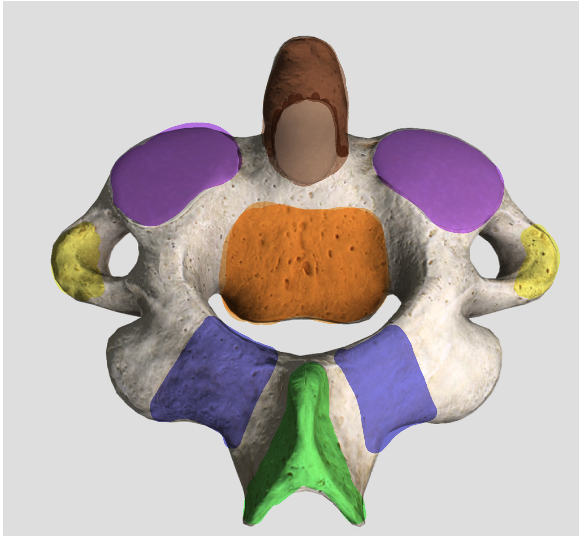


Axial Spine

C-1 Atlas
#15

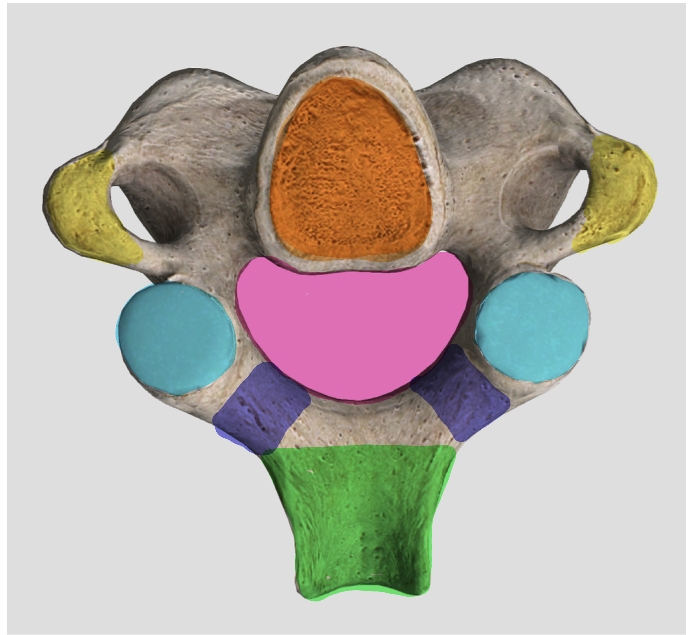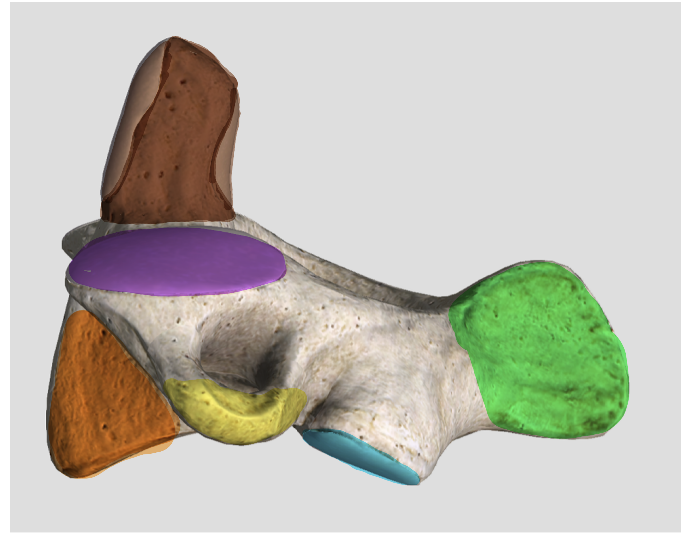


Axial Spine



C2 Axis

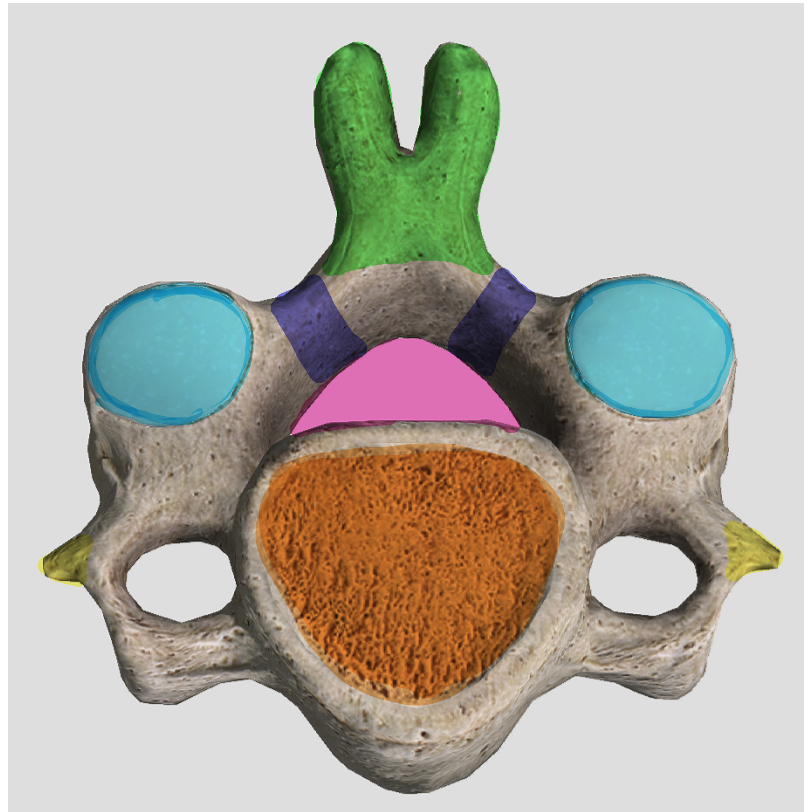
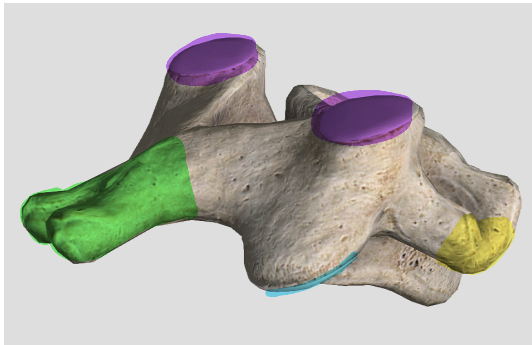
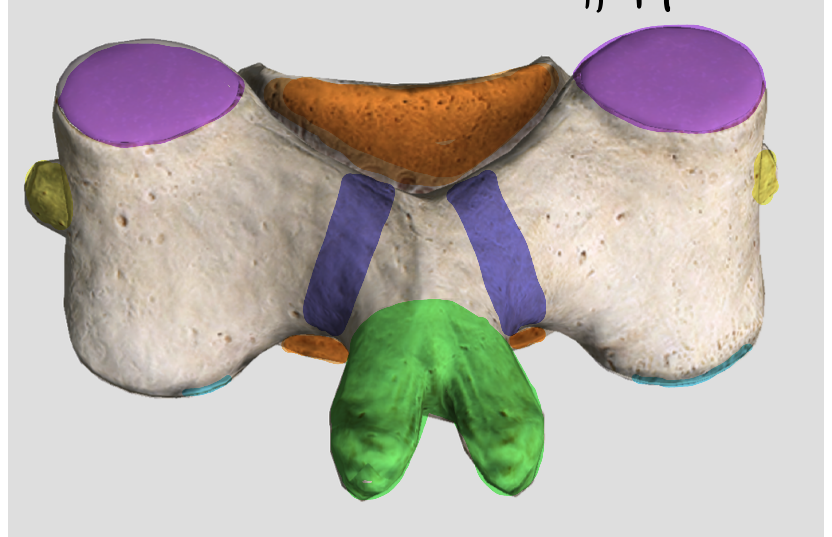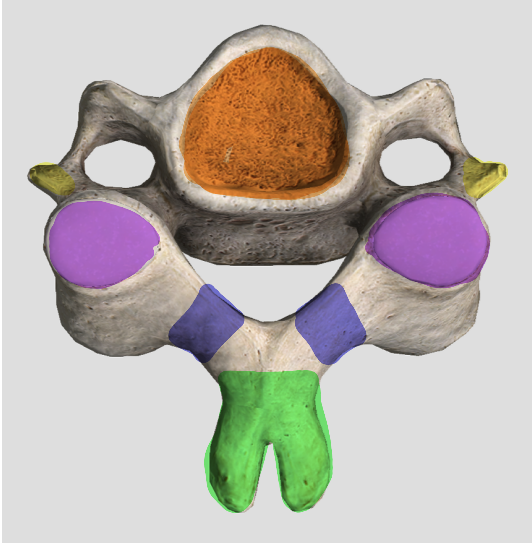
#16



Axial Spine

Typical Cervical Vertebra C3-C7*

#17

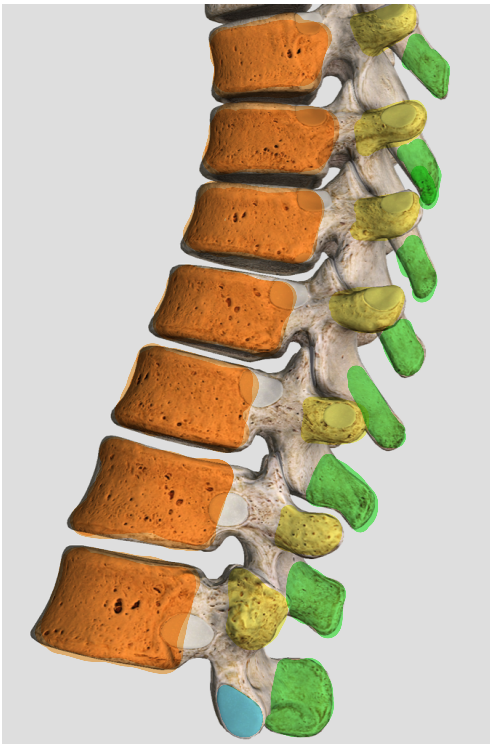
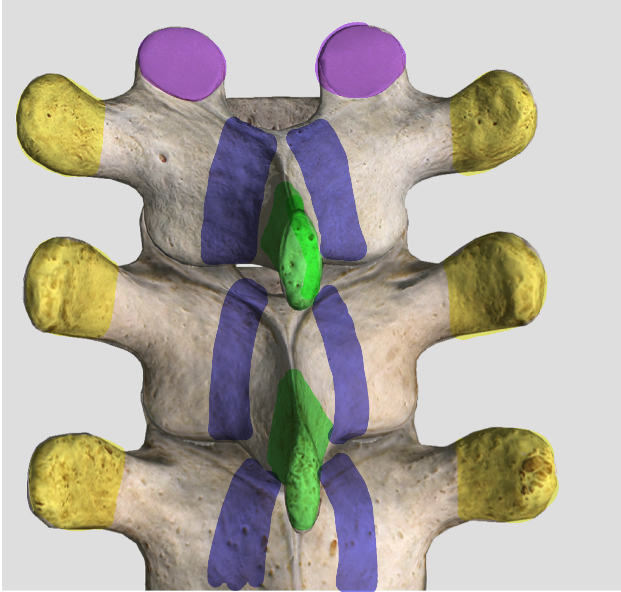
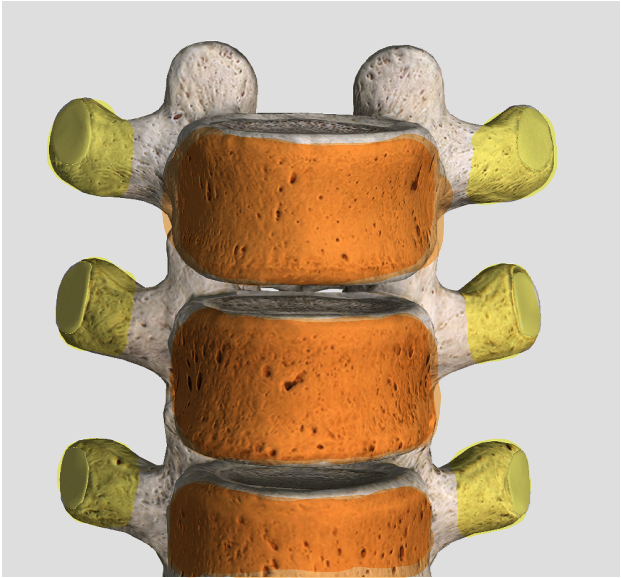
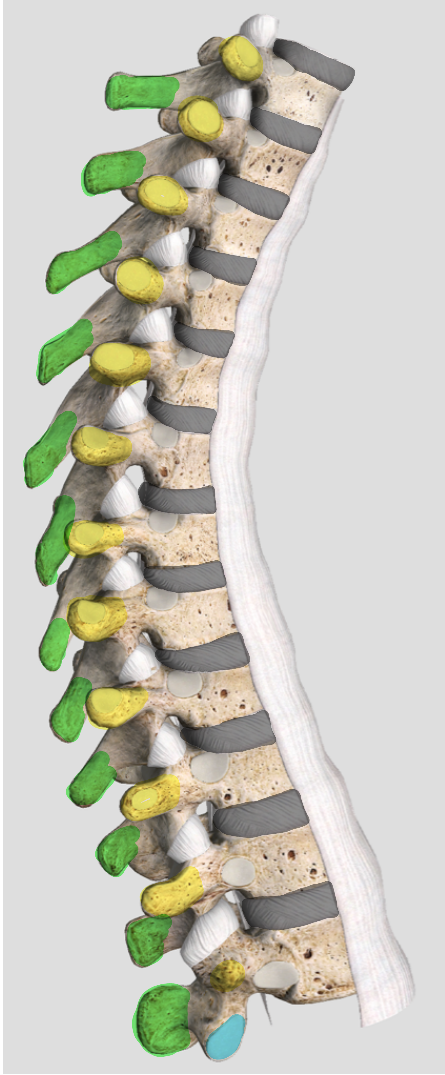
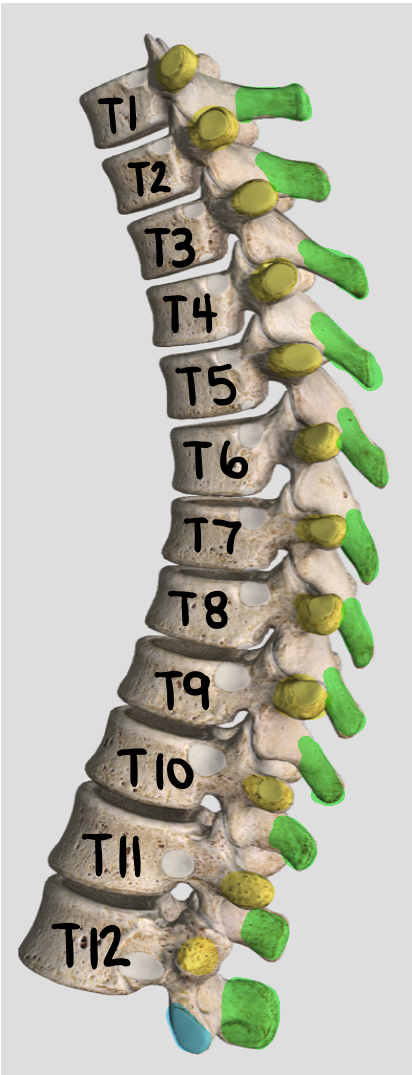


*Note C7 does not have a bifurcated spinous process.

Axial Spine

18

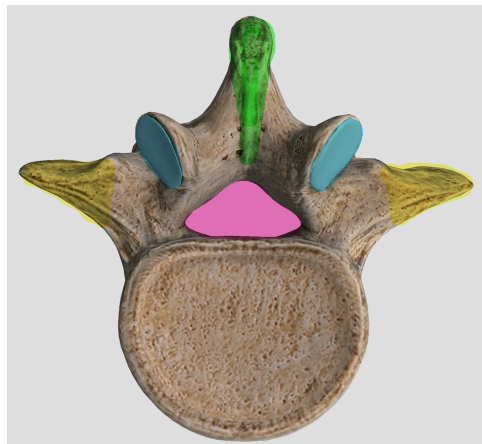
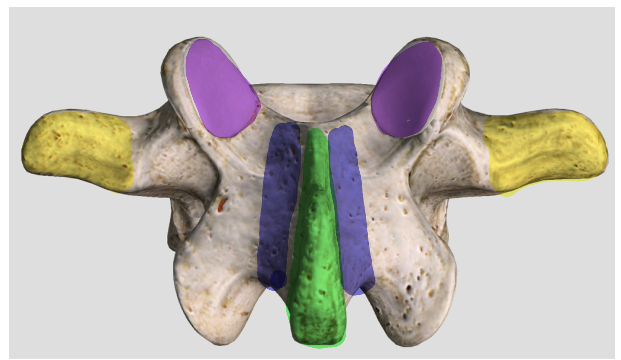
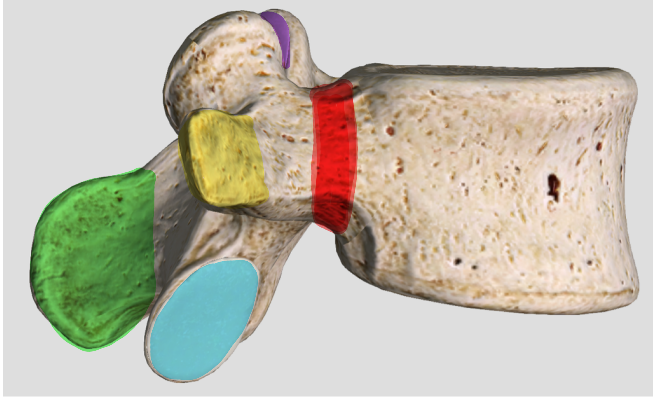
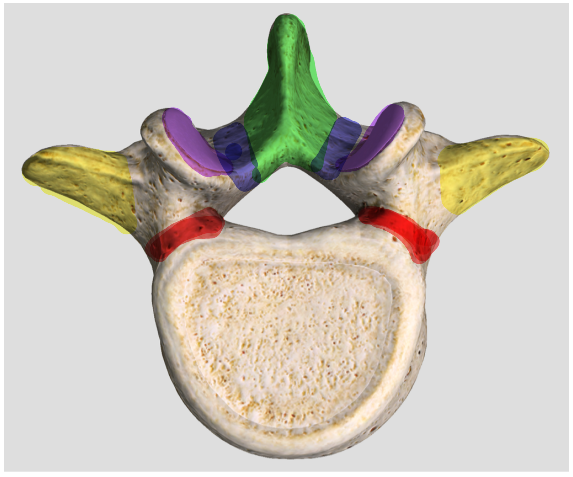

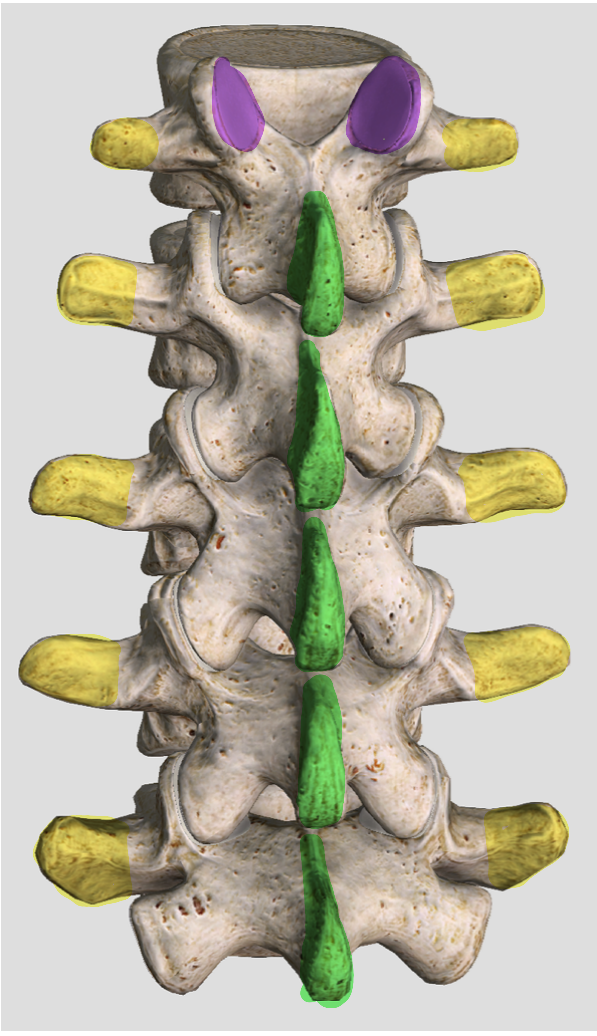
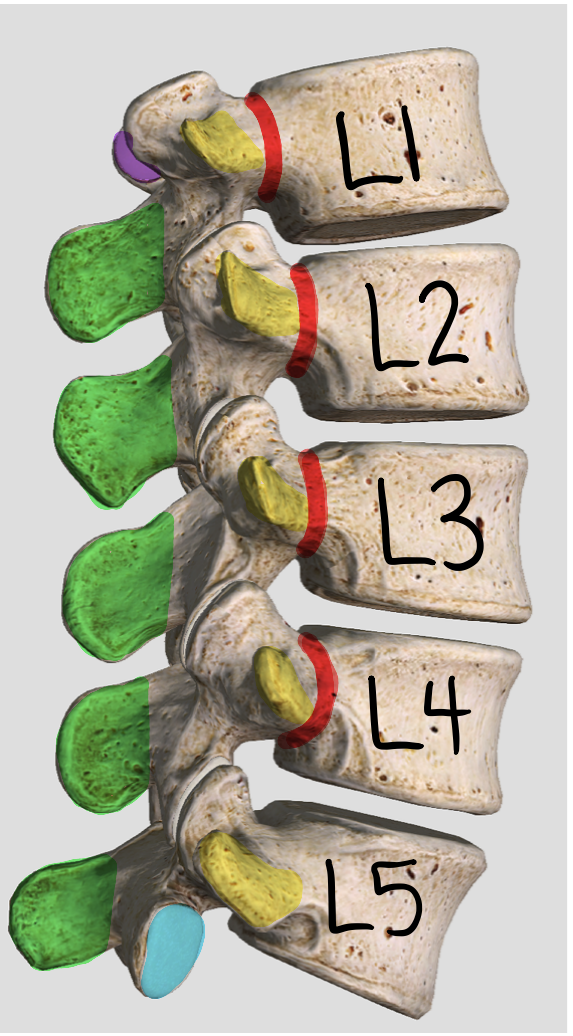
Thoracic Vertebra T1-T12



Axial Spine

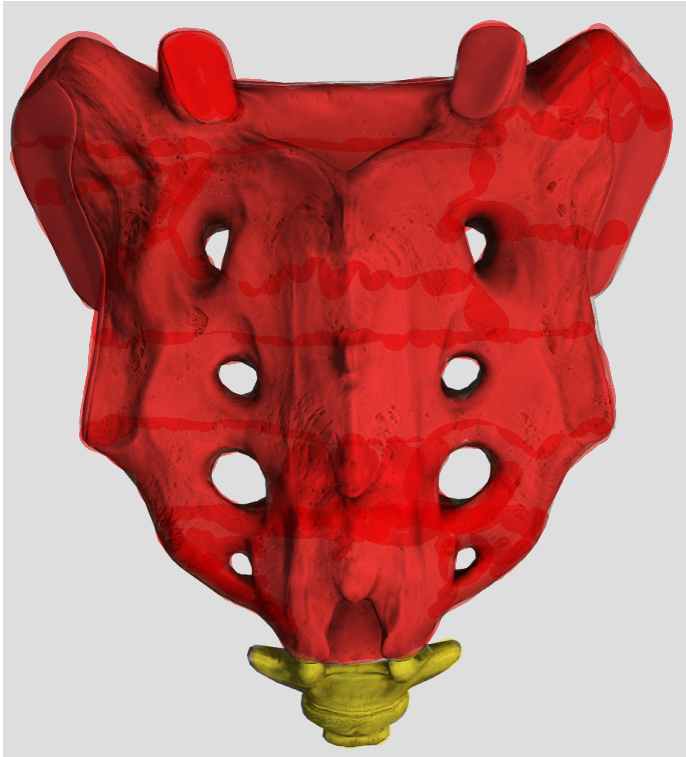
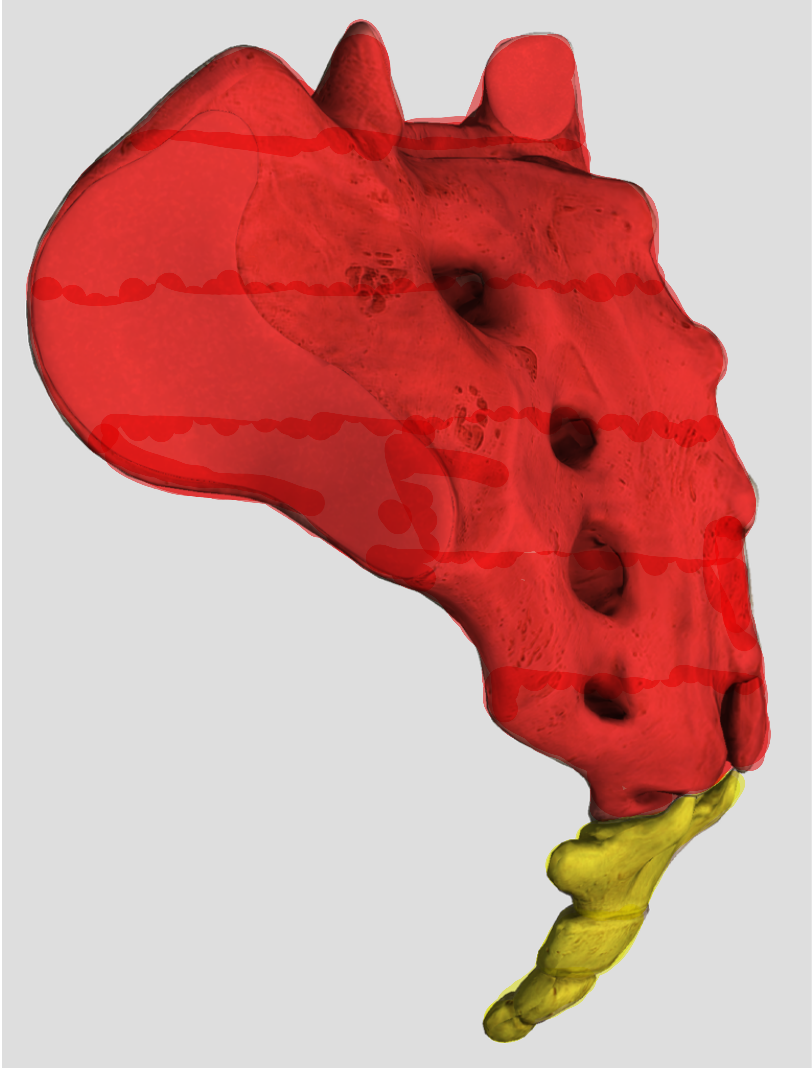
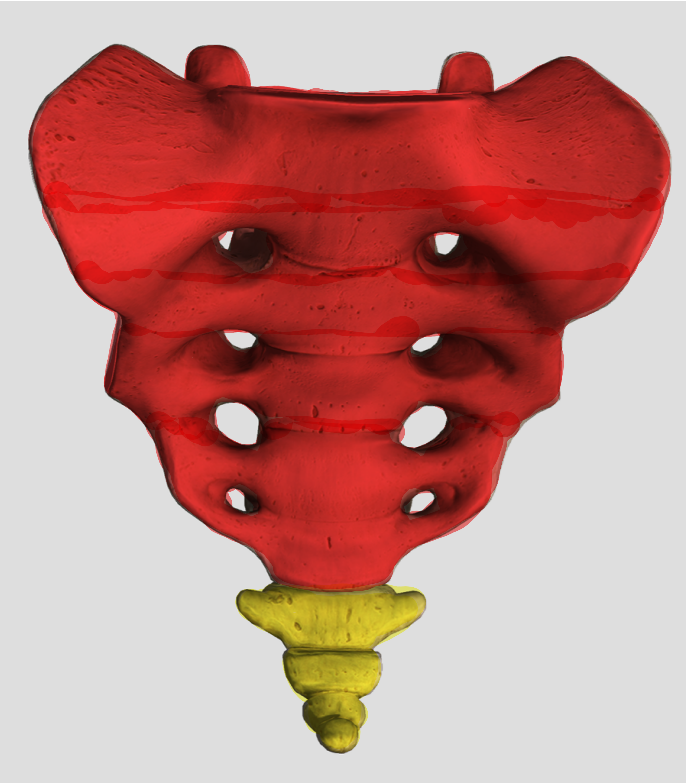
#19

Lumbar Vertebra
L1-L5



Axial Sacrum + Coccyx

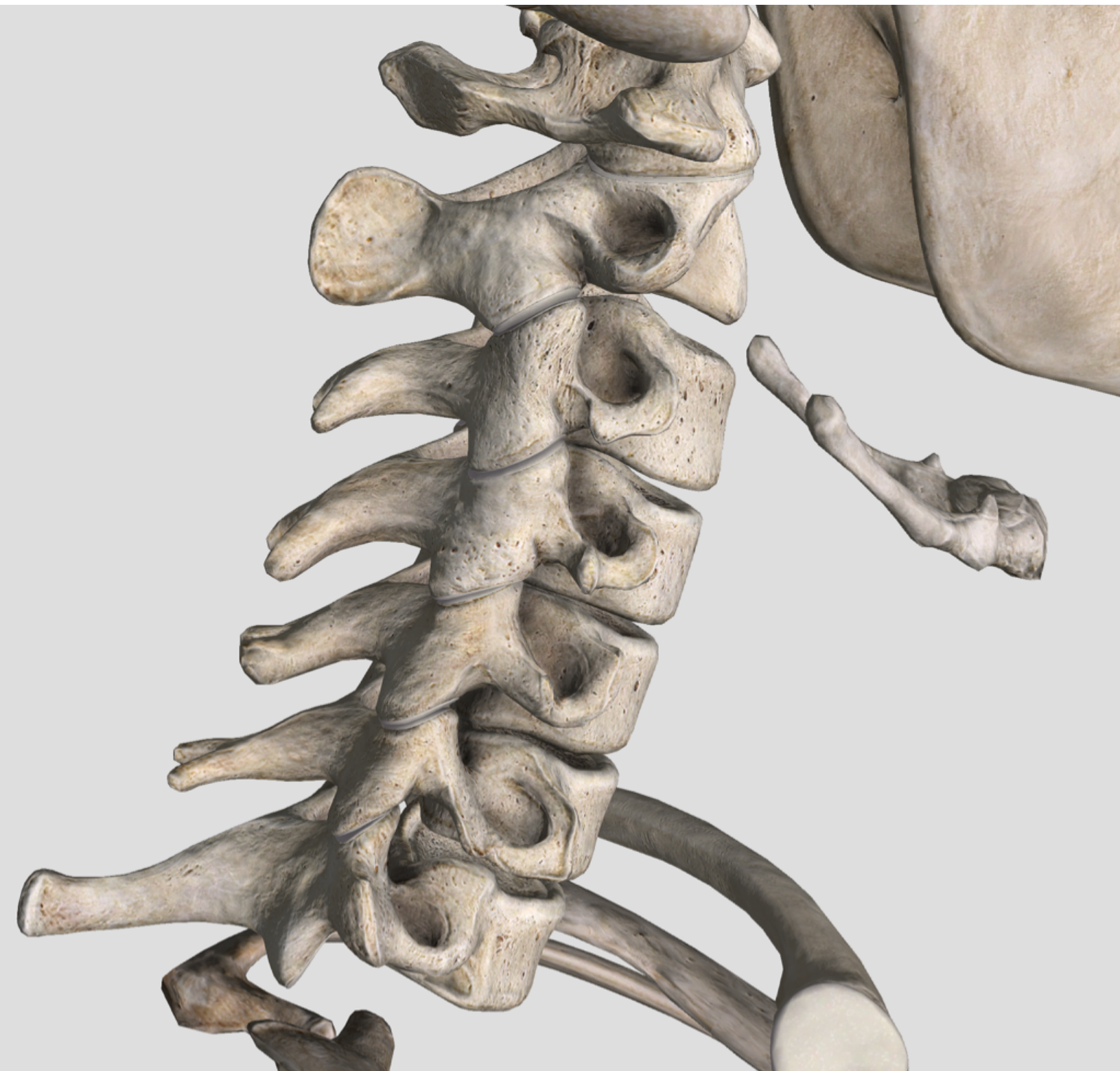#20



Axial Spine

Cervical Vertebrae

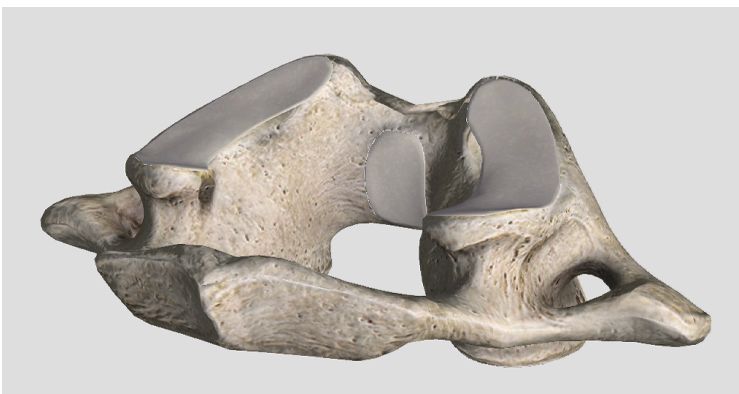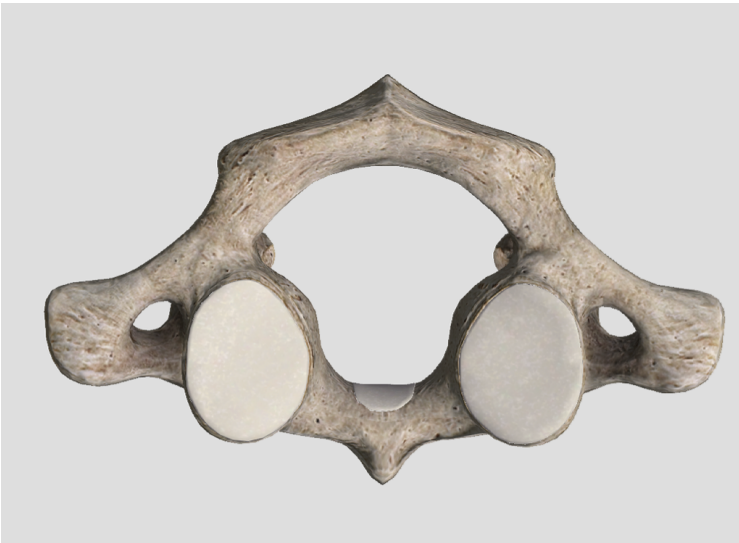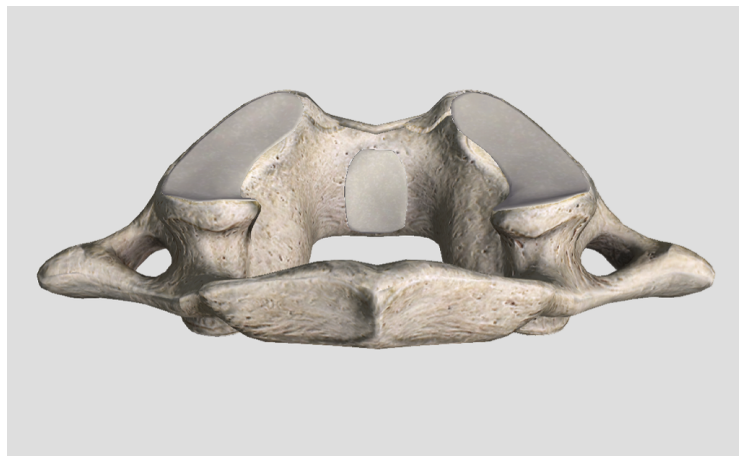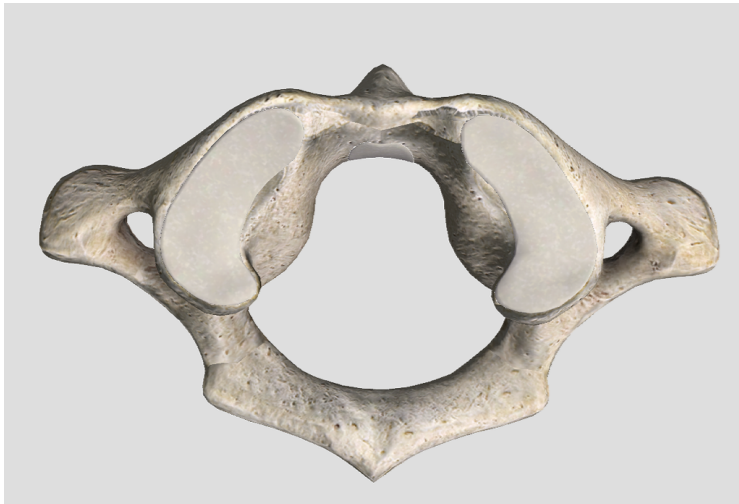#14



Axial Spine

C-1 Atlas

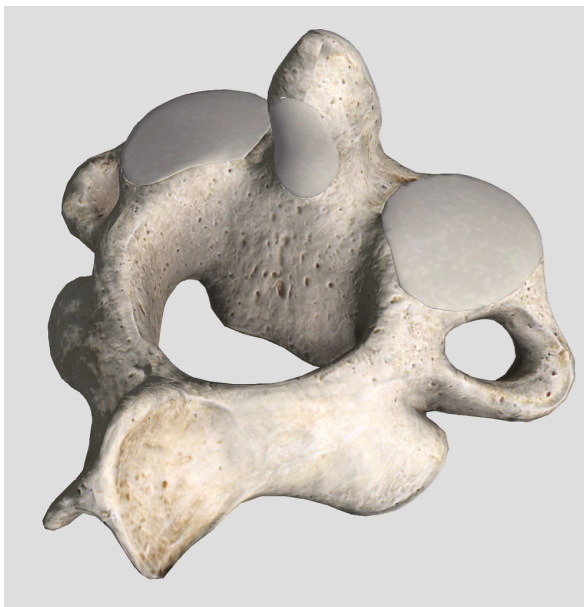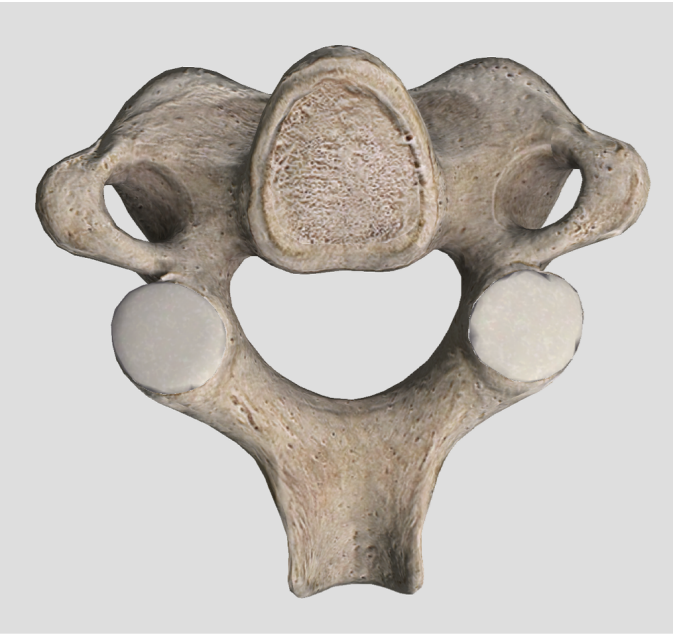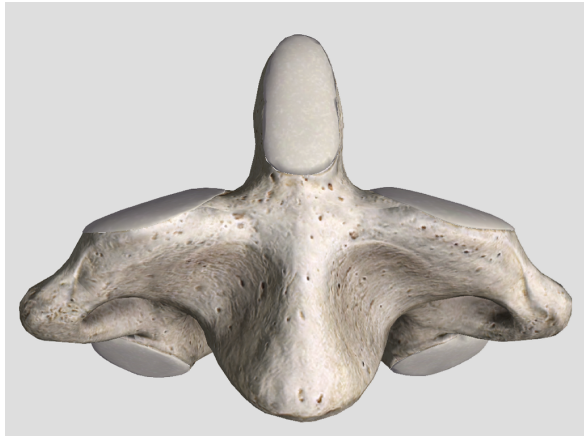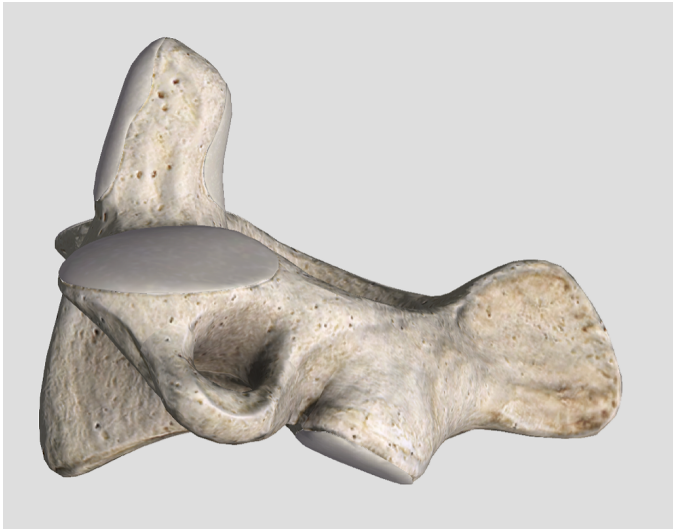
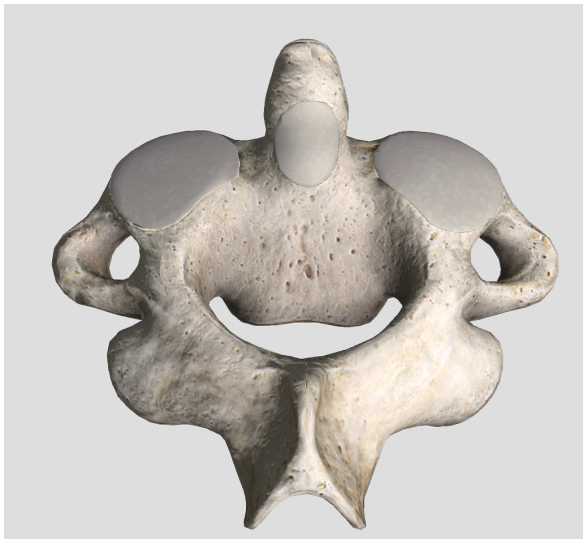#15



Axial Spine

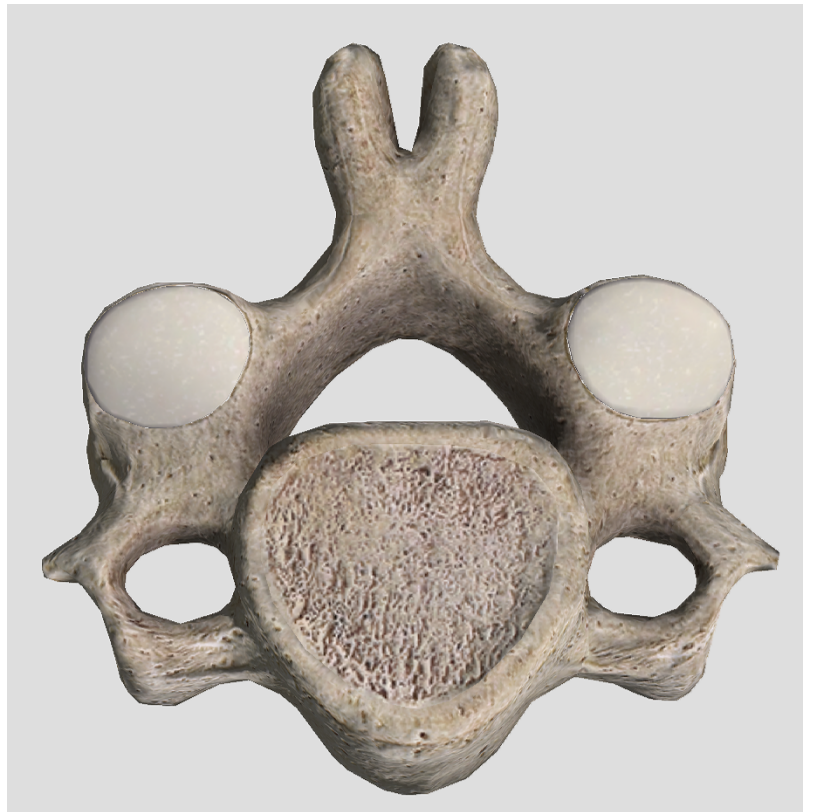
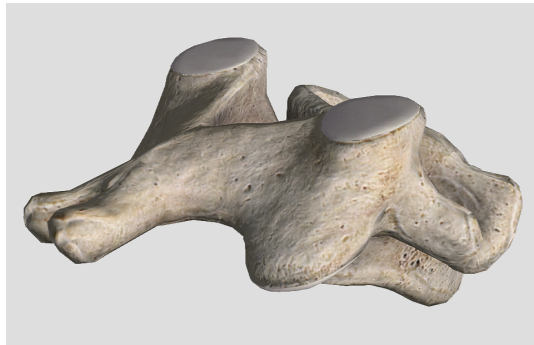
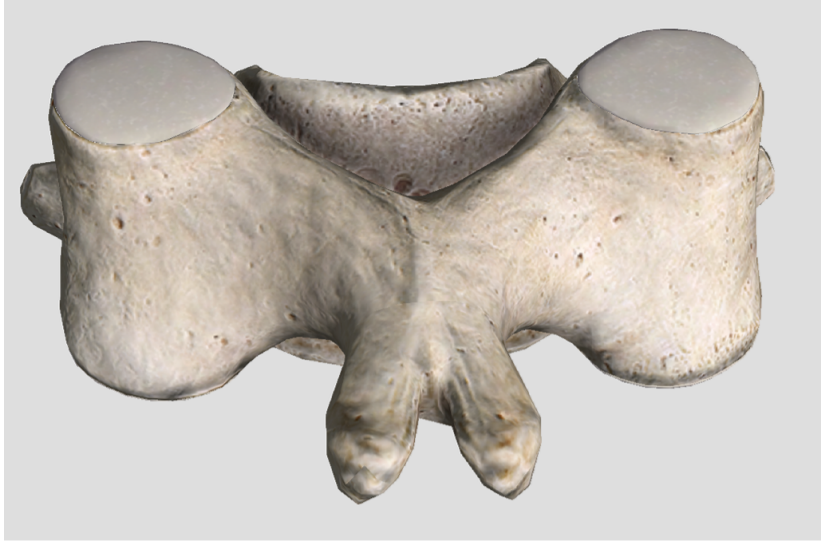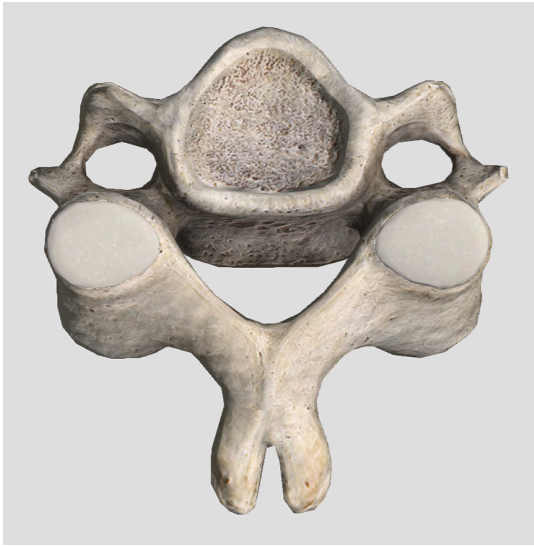C2 Axis

#16



Axial Spine

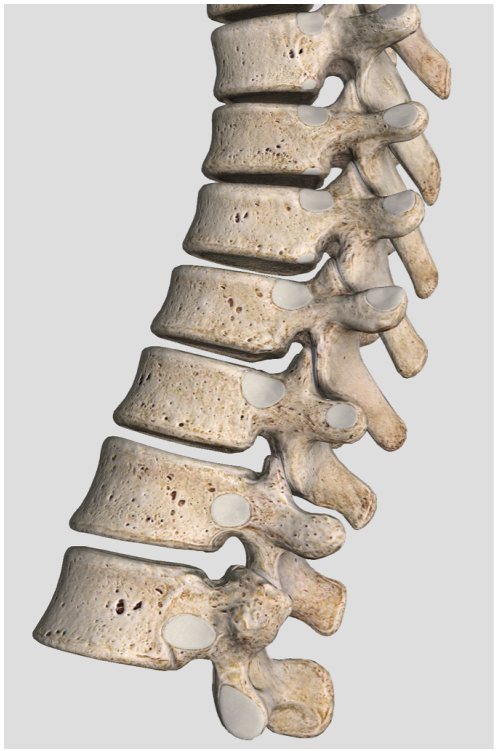
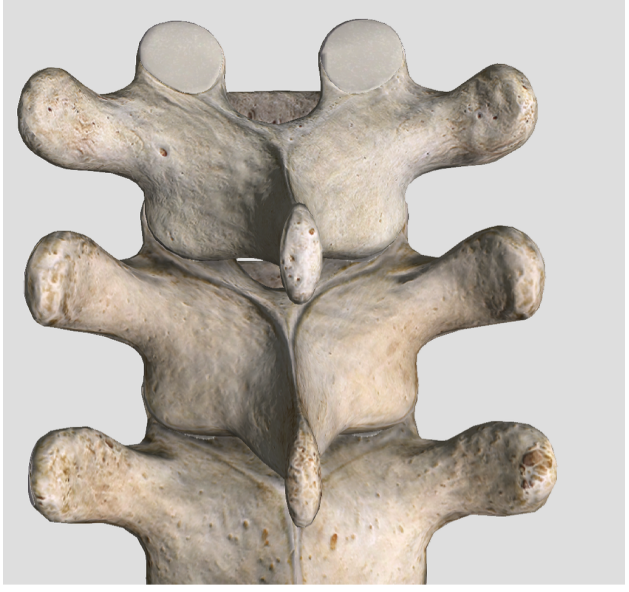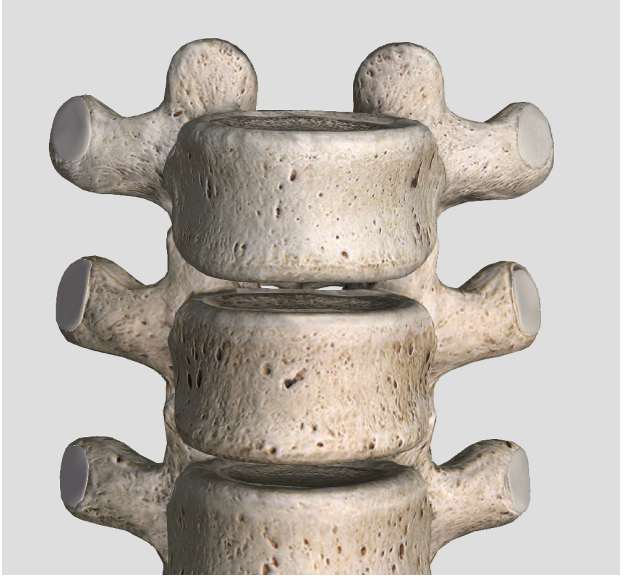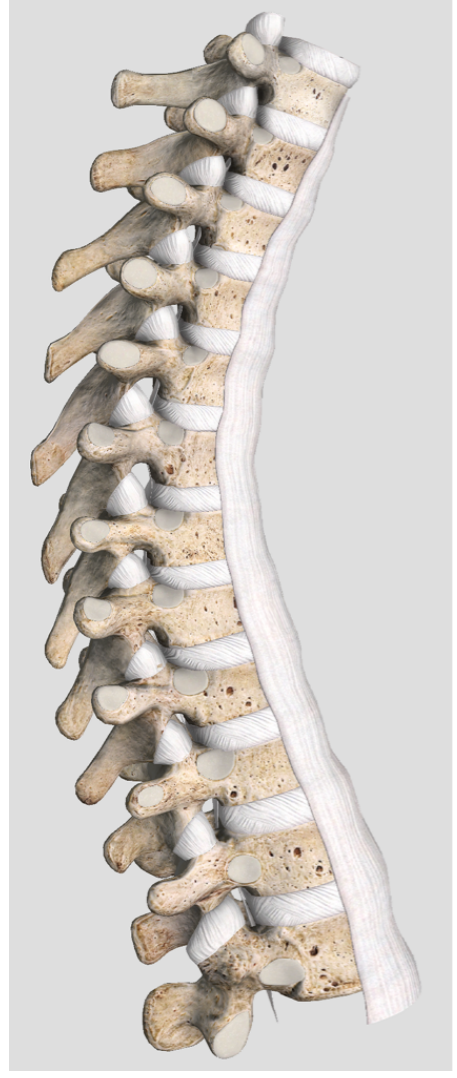
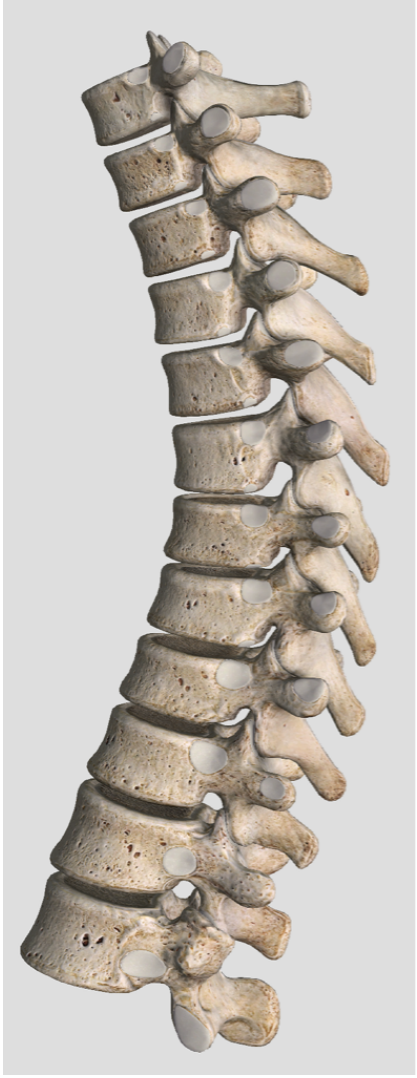Typical Cervical
#17 Vertebra C4-C7



Axial Spine

#18

Thoracic Vertebra
T1-T12

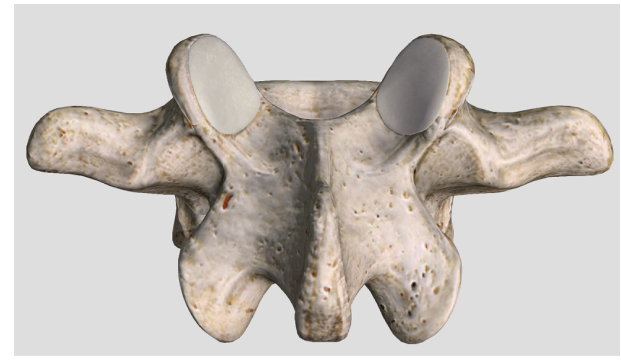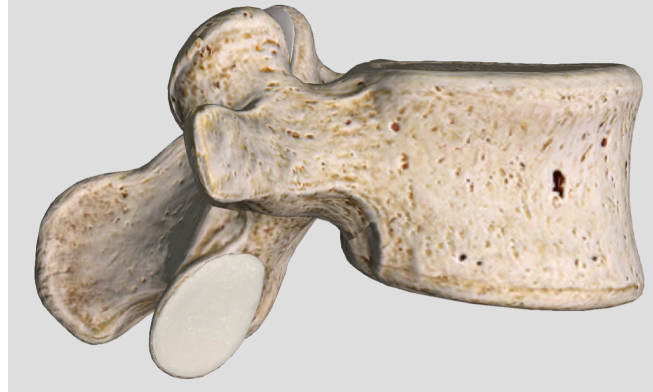
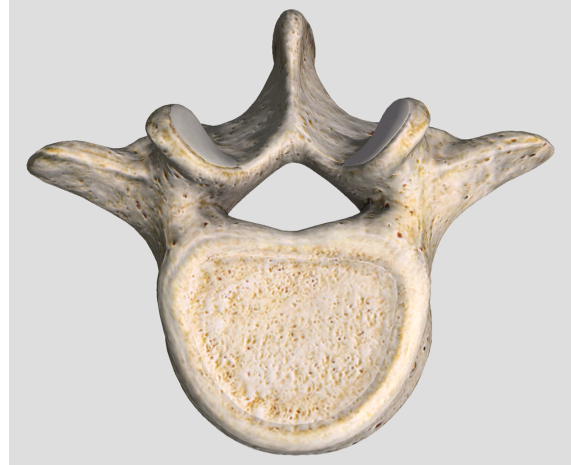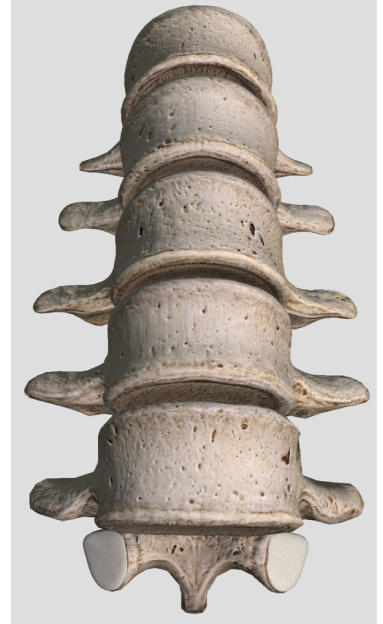
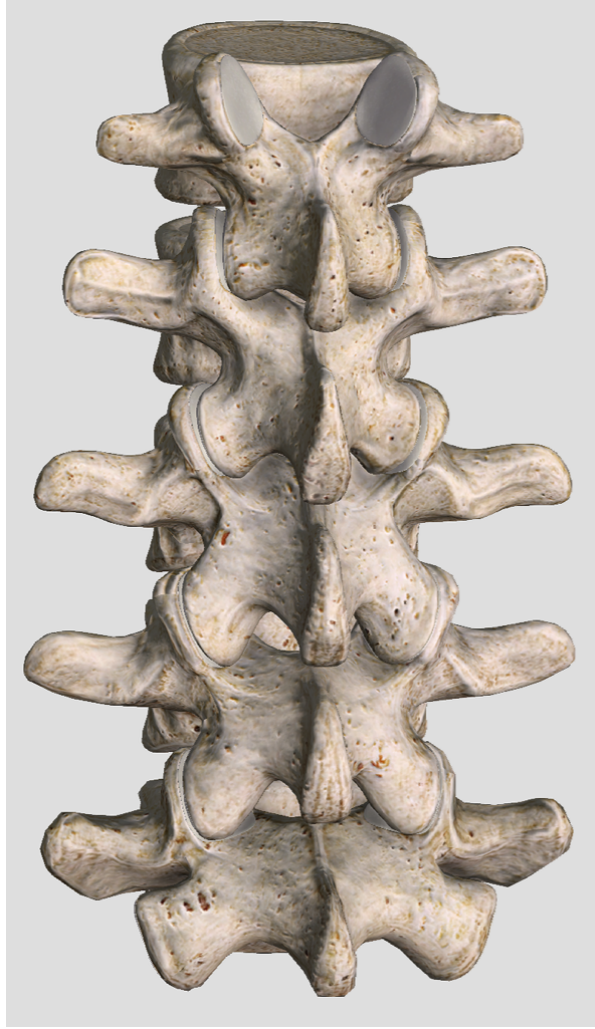
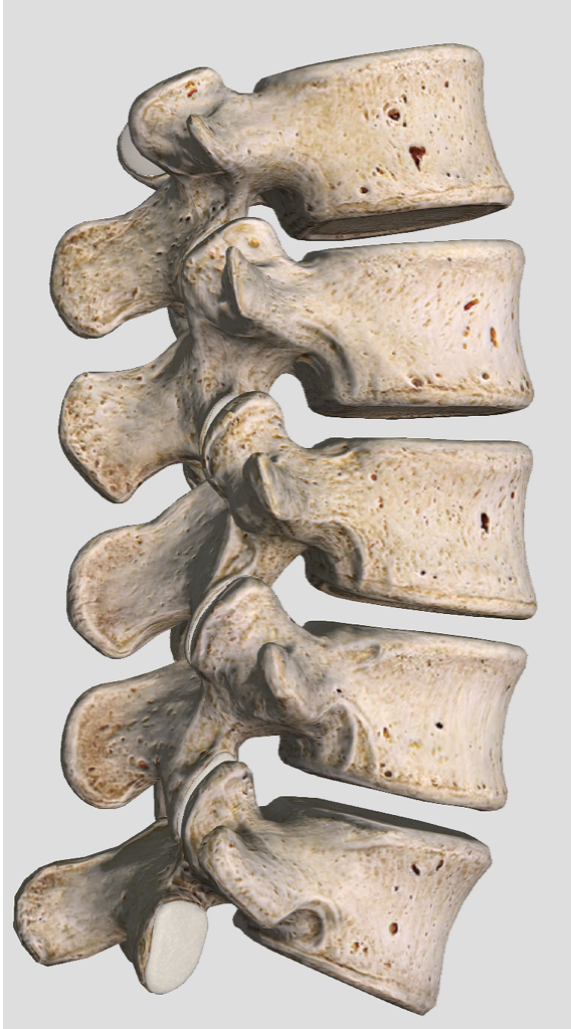


Axial Spine

#19

Lumbar Vertebra

L1-L5



Axial Sacrum + Coccyx

#20

